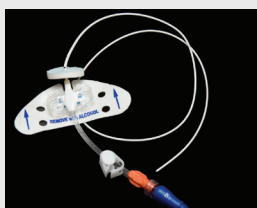


Multifactor Analysis of Malposition of Peripherally Inserted Central Catheters in Patients With Cancer

Xuying Li, RN, MSN, Honghong Wang, RN, PhD, Yongyi Chen, RN, PhD, and Zhong Yuan, RN, BSN



© Robert Byron/Hemera/Thinkstock

Background: Peripherally inserted central catheters (PICCs) are used widely in patients with cancer, but catheter malposition often occurs.

Objectives: This study aimed to provide a reference for clinically safe catheterization through multifactor analysis of malposition of PICCs in patients with cancer.

Methods: The occurrence of PICC malposition in patients with cancer was retrospectively reviewed, and a multivariate logistic regression analysis was performed.

Findings: Of 2,084 patients with PICCs, 170 cases (8%) of malposition occurred. The multivariate logistic regression analysis revealed that the risk of adverse events from malposition was higher in the right upper limb than in the left upper limb. The highest risk from malposition was cephalic vein puncture, followed by brachial vein puncture. The risk in the lower part of the elbow joint was higher than that in the upper part of the elbow joint. During PICC insertion, the left upper limb and upper part of the elbow joint should be selected for the puncture, and the basilic vein should be selected as the first-choice vein to reduce the incidence of malposition and adverse events.

Xuying Li, RN, MSN, is a PhD student in the Xiangya School of Nursing at Central South University in Changsha, China, and a vice director in the Department of Nursing at the Affiliated Cancer Hospital of Xiangya School of Medicine at Central South University/Hunan Cancer Hospital in Changsha; Honghong Wang, RN, PhD, is a vice dean in the Xiangya School of Nursing at Central South University; Yongyi Chen, RN, PhD, is a vice president in the Department of Nursing at the Affiliated Cancer Hospital of Xiangya School of Medicine at Central South University/Hunan Cancer Hospital; and Zhong Yuan, RN, BSN, is a head nurse in the Department of Vascular Access Center at the Affiliated Cancer Hospital of Xiangya School of Medicine at Central South University/Hunan Cancer Hospital. The authors take full responsibility for the content of the article. This study was supported, in part, by the fund of the Health Department of Hunan Province (B2012-090) and the Scientific Research Platform Project of Hunan Cancer Hospital. The content of this article has been reviewed by independent peer reviewers to ensure that it is balanced, objective, and free from commercial bias. No financial relationships have been disclosed by the independent peer reviewers or editorial staff. Wang can be reached at honghongwangcn@126.com, with copy to editor at CJONEditor@ons.org. (Submitted May 2014. Revision submitted September 2014. Accepted for publication October 14, 2014.)

Key words: peripherally inserted central catheter; catheter malposition; multifactor analysis

Digital Object Identifier: 10.1188/15.CJON.E70-E73

The safety and convenience of peripherally inserted central catheters (PICCs) have proven to be useful for the administration of anesthetics and toxic drugs, as well as for parenteral nutrition supply (Abedin & Kapoor, 2008; Ahn, Illum, Wang, Sharma, & Dowell, 2013). In modern nursing, PICCs have been widely used for long-term infusion in adults and children. The average retention time of a PICC line is 44–161 days (Yap, Karapetis, Lerosé, Iyer, & Koczwar, 2006). A number of significant complications are related to the insertion and maintenance of PICC lines, including catheter malposition, migration, venous thrombosis, and line fracture (Amerasekera, Jones, Patel, & Cleasby, 2009). If the catheter tip is inserted into the heart, precordial discomfort, arrhythmia, cardiac tamponade, and heart valve damage may occur (Song & Li, 2013). If the catheter remains in a peripheral vein, it may induce swelling, pain, edema of the limb, discomfort, and pain at the

site where the catheter tip is inserted through the vessel wall. In addition, the placement of the catheter tip in the jugular vein may result in discomfort, difficulty in turning the head and neck, and soreness in the affected side (Moraza-Dulanto et al., 2012). The current study aimed to evaluate and summarize the impact of factors associated with catheter malposition by evaluating a large sample of PICC cases to inform best clinical practices.

Methods

Data from 2,084 patients with cancer with PICCs inserted at vascular access centers and hospital wards were retrospectively analyzed from December 2012 to November 2013. None of the patients had a history of radiation treatment, superior vena cava (SVC) syndrome, or vascular surgery. The tumors were confirmed by pathologic diagnosis.