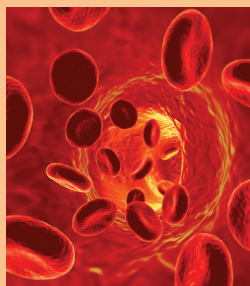


Monoclonal Gammopathy of Undetermined Significance—Making It Understandable to Patients

Pamela Rule, APRN, and Jeannine M. Brant, PhD, APRN, AOCN®



© iStockphoto.com/Thinkstock

Oncology nurses working in ambulatory care often encounter patients with nonmalignant hematologic disorders because the specialties of hematology and oncology are closely entwined. A variety of nonmalignant hematologic disorders can evolve into blood malignancies; therefore, close surveillance of nonmalignant hematologic disorders in an oncology/hematology clinic is important for early detection of malignancy. Monoclonal gammopathy of undetermined significance (MGUS) is one nonmalignant, hematologic disorder that is usually aproblematic; however, it can evolve into a blood malignancy such as multiple myeloma or be associated with other chronic conditions. This article provides an overview of MGUS with a focus on implications for the oncology nurse and patient education.

Pamela Rule, APRN, is an advanced practice nurse in the Department of Internal Medicine at Cornell Scott Hill Health Center in New Haven, CT, and Jeannine M. Brant, PhD, APRN, AOCN®, is an oncology clinical nurse specialist and nurse scientist at Billings Clinic in Montana. The authors take full responsibility for the content of the article. The authors were participants in the *Clinical Journal of Oncology Nursing (CJON)* Writing Mentorship Program. Brant received honorarium from the Oncology Nursing Society for her role as a mentor in the *CJON* Writing Mentorship Program. The content of this article has been reviewed by independent peer reviewers to ensure that it is balanced, objective, and free from commercial bias. No financial relationships relevant to the content of this article have been disclosed by the independent peer reviewers, or editorial staff. Rule can be reached at prule001@gmail.com, with copy to editor at CJONEditor@ons.org. (Submitted January 2013. Revision submitted May 2013. Accepted for publication May 12, 2013.)

Digital Object Identifier:10.1188/13.CJON.614-619

Monoclonal gammopathy of undetermined significance (MGUS) was first described by Jan Waldenström in 1960 after abnormal narrow hypergammaglobulinemia bands were noted on serum protein electrophoresis in the blood of healthy individuals (Kyle, Buadi, & Rajkumar, 2011). Robert Kyle used the term “monoclonal gammopathy of undetermined significance” in 1978 after detecting a correlation between MGUS and the development of other disorders such as multiple myeloma, Waldenström’s macroglobulinemia, amyloidosis, and chronic lymphocytic leukemia (Korde, Kristinsson, & Landgren, 2011). Therefore, MGUS is defined as the presence of an abnormal protein (monoclonal protein or M protein) in the blood or urine in the absence of end-organ damage. In 2010, the International Myeloma Working Group defined MGUS as a serum monoclonal protein under 3 g/dl with fewer than 10% clonal bone marrow plasma cells and an absence of end-organ damage, which can be attributed to the plasma cell proliferative disorder, examples include hypercalcemia, renal insufficiency, anemia, and bone lesions (Kyle et al., 2010).

Prevalence and Risk

A systematic review of 14 studies estimated that the prevalence of MGUS was about 3% in people older than 50 (Wadhera & Rajkumar, 2010). The prevalence increases with age and is estimated to be 7% in Caucasians older than 80. Additional risks include race (6% in Caucasians compared to 8% in African Americans) (Greenberg, Vachon, & Rajkumar, 2012), gender (4% of Caucasian men older than 50 years compared to 3% of Caucasian women), family history (Greenberg, Rajkumar, & Vachon, 2012), and immunosuppression. For immunosuppressed patients with HIV, a substantial risk exists ranging from 9%–45% (Wadhera & Rajkumar, 2010). Infection also has been associated with the development of MGUS. Sixty-eight percent of patients with MGUS also have had *Helicobacter pylori* infections, and the eradication of the infection led to resolution of monoclonal gammopathy in 11 of 39 patients (Kyle et al., 2011). Environmental exposure to toxins such as asbestos, pesticides, radiation, petroleum, aromatic hydrocarbons, fertilizers, and paints poses additional risk. However,