

## LETTERS TO THE EDITOR

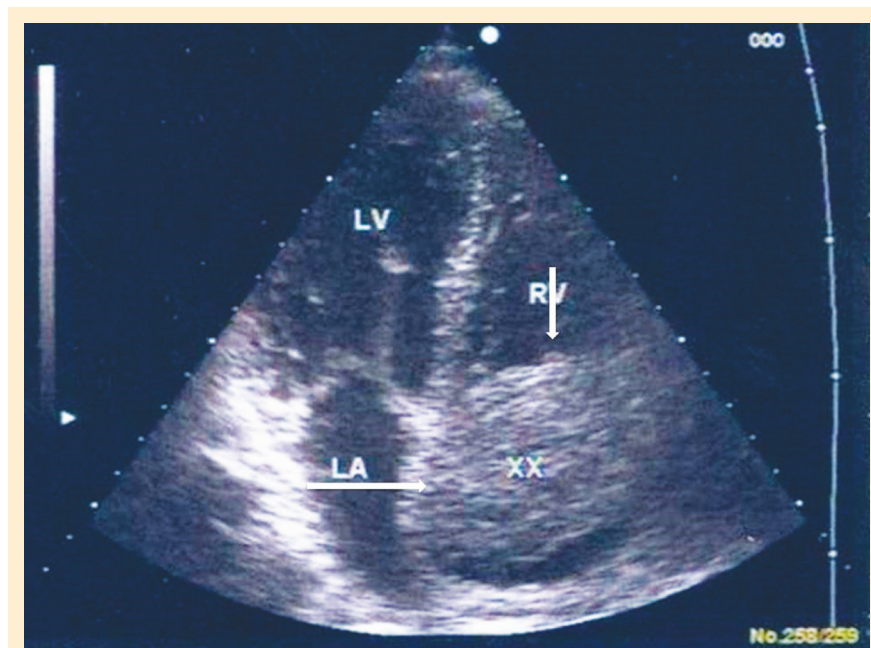
DEBORAH K. MAYER, PhD, RN, AOCN®, FAAN—EDITOR

Selection of letters to be published is the decision of the editor. For acceptance, letters must be signed. A letter can appear anonymously if requested by the author. All letters are subject to editing. A letter that questions, criticizes, or responds to a previously published *Clinical Journal of Oncology Nursing* article automatically will be sent to the author of that article for a reply. This type of collegial exchange is encouraged. Send letters to [CJONEditor@ons.org](mailto:CJONEditor@ons.org).

### Metastasis of Hepatocellular Carcinoma Into the Right Atrium

Hepatocellular carcinoma (HCC) is the fifth most common cancer worldwide and the third most common cause of cancer mortality (Jemal, Siegel, Xu, & Ward, 2010). HCC usually is diagnosed at advanced stages because of the absence of pathogenomic symptoms and the liver's large functional reserve. At the time of diagnosis, extrahepatic metastasis of HCC is found in 10%–20% of patients; the most common sites are the lung, intra-abdominal lymph nodes, bone, and adrenal gland (Yoon et al., 2007). HCC usually shows a tendency for vascular invasion, but it rarely presents with intracardiac mass. In addition, only a few cases of HCC with cardiac metastases have been reported in the literature. Herein we report a patient with a right atrial mass because of extrahepatic metastases of HCC (see Figure 1).

A 45-year-old man was admitted to the hospital with complaints of weight loss, dyspnea, abdominal swelling, and bilateral edema of the lower extremities for two weeks. The patient's medical history was unremarkable. On initial examination, the patient had a chronically ill appearance, his sclera was icteric, and cardiovascular system examination revealed a grade III–IV diastolic murmur. The patient's abdomen was distended, and generalized ascites was present with bilateral edema of the lower extremities. Laboratory findings showed elevated liver enzymes, prolonged prothrombin time, hypoalbuminemia, hyperbilirubinemia, and impaired renal functions with a high level of alpha fetoprotein ([AFP] higher than 300 mg/ml) (see Table 1). Viral markers and autoantibodies were unremarkable. Abdominal ultrasonography revealed diffuse hypoechoic appearance, massive ascites, and a mass lesion measuring 10 cm in diameter. Dynamic computed tomography showed that the liver had irregular margins and a mass lesion at the right



**Figure 1. Echocardiography of a 5 cm Mass in the Right Atrium**

Note. Courtesy of Ankara Education and Research Hospital. Used with permission.

lobe, compatible with HCC. In accordance with the imaging studies and high level of AFP, HCC was diagnosed; therefore, percutaneous liver biopsy was not performed. Transthoracic echocardiography was performed because of dyspnea and diastolic murmur, revealing a right atrial mass 5 cm in diameter. Hepatic venography and cavography showed that the inferior vena cava was occluded with tumor. The patient did not accept any therapeutic intervention and was discharged.

Tumors metastasizing to the heart are much more common than primary cardiac tumors and generally are associated with a poor prognosis. Tumors most likely to involve the heart and pericardium include cancers of the lung and breast, melanoma, lymphoma, and renal neoplasm (Abraham, Reddy, & Gattuso, 1990; Silvestri, Bussani, Pavletic, & Mannone, 1997).

HCC tends to cause vascular invasion and direct intravascular extension (Chang et al., 2004). Cardiac metastasis in patients

Erdem Koçak, MD, is a specialist of internal medicine in the Department of Gastroenterology at Ankara Education and Research Hospital; Yasar Tuna, MD, is a physician in the Department of Gastroenterology at Akdeniz University Hospital; Ibrahim Ertugrul, MD, is a physician in the Department of Gastroenterology at Türkiye Yüksek İhtisas Hospital and Mehmet Arhan, MD, is a physician in the Department of Gastroenterology at Gazi University Hospital, both in Ankara; and Seyfettin Köklü, MD, is a physician in the Department of Gastroenterology at Ankara Education and Research Hospital, all in Turkey. The authors take full responsibility for the content of the article. The authors did not receive honoraria for this work. No financial relationships relevant to the content of this article have been disclosed by the authors or editorial staff.

Digital Object Identifier: 10.1188/11.CJON.243-244