

# Idiopathic Thrombocytic Purpura

Debra Winkeljohn, RN, MSN, AOCN®, CNS

Oncology nurses often see patients with nononcologic disorders. Idiopathic thrombocytic purpura (ITP), a platelet disorder, is one such example. Being both an emergent condition as well as a chronic one, nurses will need to assess patients with ITP for bleeding and conduct extensive patient education about the disease process and treatment options.

Mrs. M is a 67-year-old woman who noticed black spots throughout her mouth. Concerned, she presented to her primary care physician who ordered a complete blood count (CBC) and conducted a physical examination (PE). Her PE was normal except for what appeared to be bruising in her mouth and a small amount of petechiae to her lower legs. Her only medication was lisinopril 20 mg daily for hypertension. Despite Mrs. M's history of hypertension, she was healthy with no prior surgical procedures or recent illnesses. Her CBC results showed a platelet count of  $3,000 \times 10^6$  U/L (normal  $150\text{--}450 \times 10^6$  U/L). Mrs. M was admitted to the hospital for evaluation of thrombocytopenia, possibly idiopathic thrombocytic purpura (ITP).

## Overview

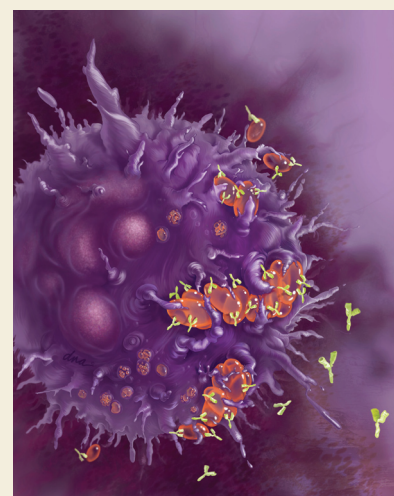
ITP is a disorder of platelet destruction and/or sequestering (George, 2009b). Patients present with lowered platelet counts often without any physical findings. ITP is a primary or secondary disorder (Goodrich, 2007). The cause of primary ITP often is unknown, but secondary ITP may be related to medications, pregnancy, recent viral infections, and transfusions (George, 2009a). Women are more commonly affected than men and ITP usually is found in women of childbearing potential. Children can develop ITP and may have spontaneous regression as they age. Adults can have spontaneous regression, although the rate is less than 5% (Goodrich, 2007).

ITP pathophysiology includes destruction of platelets because of binding of

platelets by autoantibodies in the spleen or the reticuloendothelial system (Lynch & Rogers, 2006) (see Figure 1). These autoantibodies are not necessarily seen in all patients; therefore, their use in screening or for prognostic purposes is of limited value.

Patients often present with no symptoms and ITP usually is an incidental finding when a CBC is drawn for other reasons. Some patients may present with easy bruising, petechiae, epistaxis, menorrhagia, or frank bleeding (McPhee, Papadakis, & Tierney, 2007). Major bleeding is rare in patients unless platelet counts are less than  $10,000 \times 10^6$  U/L (George, 2009a). Conservative treatment of patients with platelet counts between  $30,000\text{--}50,000 \times 10^6$  U/L are recommended because treatment often has its own side effects. Patients can live with low platelet counts for many years without increased risk of bleeding.

ITP diagnosis is one of exclusion as no definitive test for ITP exists. Patients need to have normal blood smears and normal white blood cell counts and not have a current condition or medication that can cause secondary ITP (see Figure 2). Coagulation tests usually are within normal limits. Bone marrow biopsy is not generally indicated unless patients are older than 60 years of age because of other possible causes of thrombocytopenia, such as myelodysplastic syndrome



**Figure 1. Coating of Platelets With Immunoglobulin G Autoantibodies**

Note. Copyright 2010 by DNA Illustrations/Photo Researchers, Inc. Used with permission.

(Cooper, Krainik, Lubner, Reno, & Micek, 2007). If secondary ITP is suspected, treatment is aimed at the removal of the offending cause, such as medication.

## Treatment

Treatment of ITP generally is not indicated for platelet counts greater than  $50,000 \times 10^6$  U/L. Patients who are at risk for bleeding (platelet count of less than

Debra Winkeljohn, RN, MSN, AOCN®, CNS, is the clinical director at Hematology Oncology Associates in Albuquerque, NM.

Digital Object Identifier: 10.1188/10.CJON.411-413