



Persistent Fever and Cough With Nonspecific Lower Lung Lobe Consolidation

Kathleen M. Shuey, MS, RN, AOCN®, APRN, BC

R.J. is a 34-year-old female with non-Hodgkin's lymphoma who completed her third course of cyclophosphamide, doxorubicin, vincristine, and prednisone 13 days ago. She presents to the inpatient unit with a fever of 101.4°F, blood pressure of 92/54 mm/Hg, apical pulse of 104 beats per minute, respiratory rate of 24 breaths per minute, and arterial blood oxygen saturation of 96% on room air. Physical examination is within normal limits. No adventitious sounds are noted on chest auscultation; however, she does have a nonproductive cough. In addition to blood and urine cultures, a complete blood count with differential, serum electrolytes, lactic acid dehydrogenase (LDH), a complete metabolic panel, and a hepatic panel are sent to the laboratory. She is started on ceftriaxone and vancomycin. A portable chest x-ray indicates no abnormalities. Laboratory results include a white blood cell count of 2,400/mm³ with 45% neutrophils and 1% bands, absolute neutrophil count of 1,104/mm³, hemoglobin of 11 g/dl, platelet count of 110,000/mm³, and LDH of 3,245 U/ml. Serum electrolytes, liver enzymes, and urinalysis are within normal limits.

After four days of therapy, R.J. continues to have temperature spikes above 100.5°F. Blood cultures show no growth after 72 hours. Amphotericin B and acyclovir are added to the treatment schedule. A follow-up chest x-ray reveals diffuse bilateral airspace infiltrates (see Figure 1). Serologic testing for HIV and cytomegalovirus is negative. An infectious disease consult is ordered. Sputum

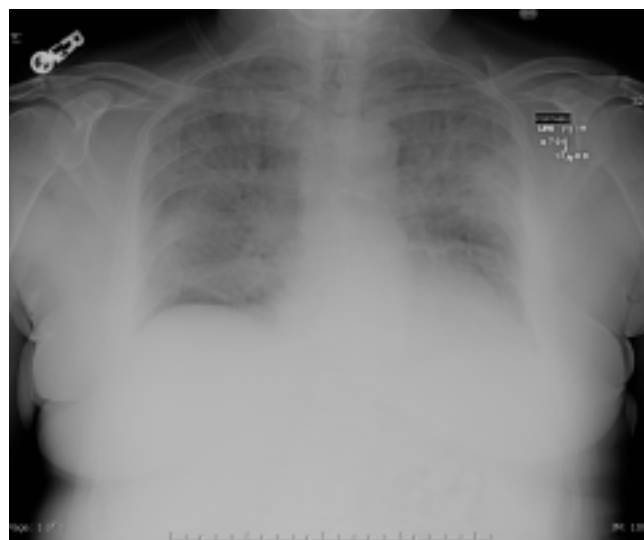


FIGURE 1. DIFFUSE BILATERAL AIRSPACE INFILTRATES

induction is negative; however, bronchoscopy with bronchoalveolar lavage indicates infection with *Pneumocystis carinii*. Amphotericin B and acyclovir are discontinued, and the patient is started on trimethoprim-sulfamethoxazole (TMP-SMX). R.J.'s chest x-ray returns to baseline after two weeks of treatment (see Figure 2).

Pathophysiology

Pneumocystis carinii is a fungal infection that is present naturally in the environment (Armstrong & Bernard, 2000; Frame & Wilkin, 2002). Serologic studies indicate that exposure can occur in children as young as two years (Centers for Disease Control and Prevention, 1992; Frame & Wilkin; Kovacs, Gill, Meshnick, & Masur, 2001), and more

than 80% of adults have antibodies to *Pneumocystis carinii* pneumonia (PCP). Active cases of PCP may result from reactivation of a latent infection or reinfection with a different strain of the organism. Infection with multiple strains has been noted in 20%–30% of patients with PCP (Agostoni et al., 2000; Beard et al., 2000; Kovacs et al.).

The route of transmission of *P. carinii* in humans is unknown, although airborne transmission (i.e., person to person or environment to person) is suspected (Armstrong & Bernard, 2000; Kovacs et al., 2001). The underlying pathophysiology of *P. carinii* also is unknown. The organism possibly attaches to areas on alveolar macrophages, and in binding to type I alveolar epithelial cells, the basement membrane degenerates and normal surfactant function is impaired. An eosinophilic, foamy exudate develops that fills the alveolar space and leads to impaired gas exchange. Although rare, bullous cavities may develop, usually in the

Kathleen M. Shuey, MS, RN, AOCN®, APRN, BC, is a nurse manager of education and admixture implementation at U.S. Oncology in Albuquerque, NM. (Mention of specific products and opinions related to those products do not indicate or imply endorsement by the Clinical Journal of Oncology Nursing or the Oncology Nursing Society.)

Key Words: pneumonia, pneumocystis carinii; HIV; anti-infective agents

Digital Object Identifier: 10.1188/03.CJON.463-466