



Management of Malignancy-Related Ascites

Anne Marie C. Flaherty, MSN, RN, APNC, AOCNS®

A 65-year-old Polish immigrant named T.J. was diagnosed with metastatic colon cancer in January 2012 when he presented with obstructing sigmoid colon cancer and liver metastases. A diverting colostomy as well as biopsy of his liver metastases was performed and chemotherapy with FOLFOX (5-fluorouracil [5-FU], leucovorin, oxaliplatin) and bevacizumab was initiated. After three months, he transitioned to maintenance therapy with infusional 5-FU and bevacizumab until he progressed in August 2012. Oxaliplatin was reintroduced and he responded until he developed progressive neuropathy in November and his therapy was changed to FOLFIRI (5-FU, leucovorin, irinotecan) and bevacizumab. T.J. developed liver progression after three months and, because he was *Kras* wild type, irinotecan and panitumumab were initiated. Liver-directed therapy also was pursued and he underwent radioembolization with yttrium-90 followed by chemoembolization with irinotecan-eluted beads. At the time of these procedures, T.J.'s portal and hepatic venous systems were patent (i.e., no thrombosis or obstruction causing portal hypertension).

T.J. did well for seven months until he developed liver progression and, because his neuropathy had significantly improved, FOLFOX was reintroduced. He developed ascites after three months of therapy, with abnormal liver function tests and an elevated bilirubin as well as lower extremity edema. Computed tomography (CT) scans revealed progression of disease with no biliary duct dilatation, and liver dysfunction was attributed to parenchymal disease. A therapeutic paracentesis was performed and 4 L of straw-colored ascites were drained with cytology revealing malignant cells, consistent with a colon

adenocarcinoma. T.J.'s ascites rapidly reaccumulated and he underwent another paracentesis one week later. An indwelling intraperitoneal drainage catheter was suggested to allow more convenient drainage at home and a Tenckhoff catheter was inserted.

Arrangements were made to obtain proper equipment as well as a visiting nurse to assist with home drainage. Dressing and cap changes were performed aseptically on a weekly basis or more often if needed. Drainage was performed by twisting the cap, which allowed fluid to drain out of the catheter and into a container. T.J. had difficulty with leakage around the catheter because of his rapid accumulation of ascites. He was draining 3–4 L twice per week but, when the schedule was changed to 1 L per day, leakage improved.

At an office visit, T.J. complained of abdominal pain, nausea, vomiting, and a low-grade fever. Skin around the catheter did not appear to be infected and leakage was minimal. T.J. was admitted to the hospital and CT scans revealed wall thickening of the transverse and sigmoid colon most consistent with inflammation or infectious etiology. The ascitic fluid was cultured and positive for enterbacter species and *Stenotrophomonas maltophilia*. He was treated with triple antibiotics, vancomycin, sulfamethoxazole-trimethoprim, and linezolid, and the indwelling intraperitoneal drainage catheter was removed. T.J. recovered from his infection; unfortunately, his liver dysfunction progressed and he died during his hospitalization.

This case sparked a quality improvement initiative to examine the catheters, equipment, and procedures used to manage outpatient peritoneal drainage catheters at the author's institution. A collaborative effort included office, infusion, and interventional radiology nurses,

physicians from interventional radiology, infectious disease and the wound care service, as well as consultation with other institutions and medical equipment companies. Principles of management of an indwelling peritoneal catheter and drainage of malignant ascites will be addressed.

Malignancy-Related Ascites

Malignancy-related ascites are caused primarily by three conditions: peritoneal carcinomatosis, extensive liver metastases, or a combination of both (Runyon, 2014; Runyon et al., 1992). Malignant tumors, such as gastric, colon, pancreas, lung, and breast, are most often associated with liver metastases and peritoneal carcinomatosis, whereas ovarian and bladder cancers most frequently cause peritoneal carcinomatosis. Lymphoma can obstruct lymphatic drainage, resulting in chylous ascites, and hepatocellular cancer (HCC) occurs in the setting of cirrhosis of the liver, which also is associated with ascites (Runyon, 2014). This article will not address malignant ascites of lymphoma or HCC.

Malignancy-related ascites of advanced cancer carries a poor prognosis and limited lifespan of one to four months, except in untreated ovarian cancer (Ayantunde & Parsons, 2007). Ovarian cancer is very chemosensitive and responds to systemic as well as intraperitoneal chemotherapy and has a different disease trajectory. Ascites will affect the patient's quality of life, causing an array of symptoms such as abdominal distention and discomfort, shortness of breath, anorexia and early satiety, nausea and vomiting, reflux, lower extremity edema, fatigue, and decreased mobility (Tapping, Ling,

ONF, 42(1), 96–99.

doi: 10.1188/15.ONF.96-99

& Razack, 2012). Efficient and safe management of this debilitating complication of cancer will certainly affect quality and palliation at the end of life.

Pathogenesis

Ascites had been classified as transudative and exudative based on protein analysis of the ascites to distinguish whether the ascites were primarily driven by portal hypertension versus peritoneal carcinomatosis. The serum ascites albumin gradient (SAAG) is a more accurate method to identify portal hypertension. SAAG is determined by subtracting the albumin level in the ascites from the serum albumin level, both obtained on the same day (Runyon, 2014). Low-gradient SAAG ascites (< 1.1 g/dl) are associated with peritoneal carcinomatosis, which is the most common cause of malignant ascites, and account for 53% of cases. Low-gradient SAAG ascites were previously classified as exudative ascites and are most commonly seen in patients with ovarian cancer, bladder cancer, peritoneal mesothelioma, and other solid tumors without significant liver metastases (Runyon, 2014). High-gradient SAAG ascites (≥ 1.1 g/dl) are associated with liver metastases and portal hypertension and account for 13% of cases. This type of malignant ascites was previously referred to as transudative ascites and most often

are seen in patients with liver metastases, cirrhosis, hepatocellular cancer, and portal vein thrombosis (Runyon, 2014). Another 13% of cases are attributed to both peritoneal carcinomatosis and liver metastases, and the remaining cases are from other causes (Runyon, Hoefs, & Morgan, 1988). Ascites from peritoneal carcinomatosis develops as a result of increased capillary permeability, blockage of lymphatic vessels, and decreased efflux from the peritoneal cavity. Ascites associated with massive liver metastases are a consequence of portal hypertension, which alters intestinal capillary pressure and permeability and causes compression of the portal veins (Rosenthal, 2009).

Management

Paracentesis is performed initially to relieve symptoms and to obtain analysis of the ascites. Glucose, protein, cell count, culture, SAAG, and cytology are obtained to identify the cause and characteristics of the ascites. The volume of fluid that can safely be removed is determined by the type of ascites. When ascites are caused by peritoneal carcinomatosis, amounts greater than 5 L can be drained versus when portal hypertension and cirrhosis are the cause. The latter present a less hemodynamically stable condition if large amounts of ascites are drained. The use of colloid- or albumin-based infusions with paracentesis is controversial, and no evidence supports their routine use unless the patient is hemodynamically unstable after the procedure.

Complications of performing a paracentesis are low but include infection or peritonitis, intestinal perforation, hypoproteinemia, hypotension, and pulmonary embolus (Chung & Kazuch, 2008). The ascites reaccumulate in an average of 7–10 days, requiring repeated paracenteses, which exposes the patient to repeated risk of complications and numerous trips to the hospital for the procedure (Becker, Galandi, & Blum, 2006). Diuretics and a low-sodium diet can help reaccumulation, but have been found to be effective only in those patients who have ascites from portal hypertension and liver metastases, which is about one-third of all cases (Cavazzoni, Bugiantella, Graziosi, Franceschini, & Donini, 2013). Portal hypertension results in elevated levels of plasma renin and aldosterone, which can respond to spironolactone and furosemide. The recommended dosages to begin are 100

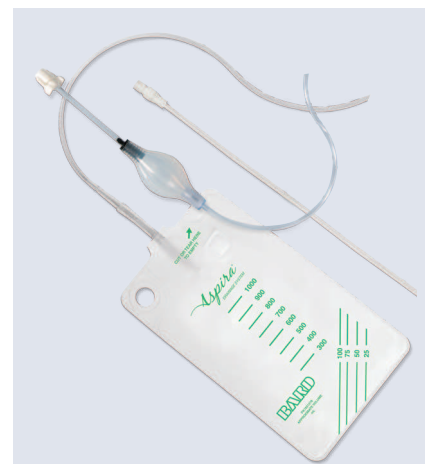


Figure 2. Aspira® Drainage System

Note. Image courtesy of C.R. Bard, Inc. Used with permission.

mg spironolactone and 40 mg furosemide and may be increased while keeping the proportion the same (Cavazzoni et al., 2013). Clinicians often institute diuretics in all patients because some may have a component of portal hypertension with peritoneal carcinomatosis.

Because of a lack of large, randomized clinical trials, no evidence-based guideline or standard exists for the management of malignancy-related ascites. Alternatives to repeated paracenteses have been explored, and one alternative is peritoneovenous shunts such as Denver® or LeVeen®. These have been deemed high risk and expensive, and they often malfunction (Schumacher, Saclarides, & Staren, 1994). Complications include pulmonary embolism, disseminated intravascular coagulation, pulmonary edema, and occlusion. They are not recommended for patients with malignant ascites (Runyon, 2014). Experience with intraperitoneal dialysis led to the use of Tenckhoff catheter for ascites management. The concept of a tunneled, cuffed catheter for home drainage of ascites would increase the convenience and improve the comfort and quality of life for patients with refractory ascites. Experience revealed a relatively low infection and complication rate (O'Neill, Weissleder, Gervais, Hahn, & Mueller, 2001). However, problems arose with leakage, ease of drainage, and access to appropriate equipment because it was not approved by the U.S. Food and Drug Administration (FDA). Those were the issues facing the staff and patient in the case study.

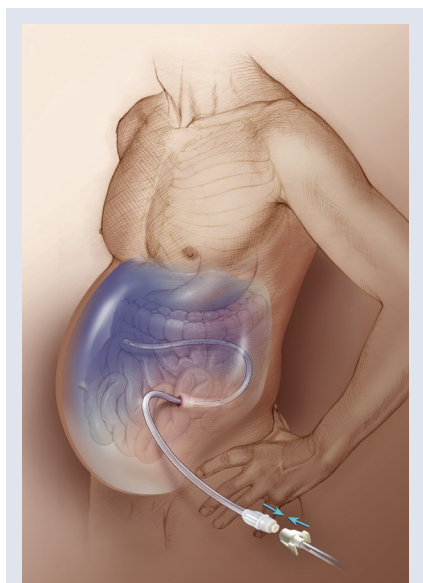


Figure 1. Tunneled Catheter With Aspira® System

Note. Image courtesy of C.R. Bard, Inc. Used with permission.

Principles of a Home Drainage System

Effective and safe ascites drainage in the patient with malignant ascites is a priority to palliate this distressing symptom. It was identified that a catheter that could be easily inserted and adequately drain ascites with minimal complications was needed (see Figure 1). Systems that were used for drainage of pleural effusions in an outpatient setting and at home were then applied to malignant ascites. The physical characteristics that were needed were a tunneled cuffed catheter with a one-way valve to reduce leakage around the catheter and infection rate and a closed-drainage system that accesses the one-way valve, which would further decrease infection. The drainage system also needed to be one-time use and disposable. Two drainage systems that met these requirements were the Aspira[®] and PleurX[®] systems (see Figures 2 and 3). Both are FDA approved for the management of malignant ascites.

The design of the catheters and insertion technique has reduced leakage around the catheters, which was a major issue with the Tenckhoff catheters (Shuman, 2008). Leakage led to skin maceration and superficial cellulitis. The superior-lateral insertion and coating of the catheters also reduces leakage

during and after insertion. The one-way valves on the distal end are an intrinsic part of the catheters, resulting in less manipulation changing the valves or caps, as was required with the Tenckhoff. These valves lock into the drainage tubing, providing a closed or one-way drainage system and a simple process for the patient and caregiver, which further reduces the risk of infection (Behrendt, 2008).

Both systems also provide facilitation of drainage with vacuum-enhanced technology. The Aspira system has a low-vacuum, siphon-activating pump built into the drainage tubing that, when pressed and activated, promotes drainage of the ascites. PleurX uses a vacuum bottle that is activated when the tubing is inserted. The systems also provide clamps on the tubing so that if accidental breakage of the catheter occurs, the system can be sealed. Drainage can be completed in as little as 15 minutes. Both systems have maximum drainage capacity of 1,000 ml. If a larger volume is needed, a second drainage system would be used. The exit site of the catheter requires routine dressing changes, and Aspira and PleurX provide dressing supplies. Dressings should be changed weekly or if they become wet, dislodged, or saturated with drainage. Shuman (2008) recommended the Aspira system, saying it was less cumbersome and less costly; however, Behrendt (2014) preferred the PleurX system for its efficiency in drainage.

Nursing Management With Peritoneal Catheters

Large-volume paracenteses on an outpatient basis can provide adequate management for patients with poor performance status and limited life expectancy (Runyon, 2014). Certain conditions occur when an indwelling peritoneal catheter is contraindicated, including presence of infection or peritonitis, significant coagulopathy, loculated ascites, poor patient and family compliance, and financial constraints (Bard Access Systems, 2012). Each company, however, does have a patient-assistance program. Patient selection is based on absence of contraindications, fair performance status to undergo the procedure, and life expectancy beyond a few weeks.

When a patient requires a weekly paracentesis, the indwelling peritoneal catheter is an option to reduce the trips

to the outpatient facility, eliminate the pain associated with the procedure, and provide autonomy to the patient for drainage at his or her convenience. The other positive aspect is that the every-other-day drainage at home allows for small but frequent drainage. This allows a residual amount of ascites to act as a girdle to prevent the rebound reaccumulation of ascites that occurs after a traditional large-volume paracentesis. This can result in less protein loss and hemodynamic fluctuations (Mullard, Bishop, & Jibani, 2011). The recommended drainage schedule is 1–2 L every other day for those patients performing drainage at home (CareFusion, 2014). The infection rate with these catheters is less than 5% (Courtney et al., 2008).

Patient education is a crucial element to the success of managing malignant ascites at home. Coordination of the insurance approval, insertion, procurement of supplies, and adequate support with home care require a team designated to providing these services. Preprocedure instructions, laboratory assessments, and insurance approval will expedite insertion of the catheter. Homecare follow-up and coordination of delivery of supplies are needed to ensure that the patient and caregiver

Aspira[®]

For Patients

Patient brochure, drainage instruction chart, kits and ordering supplies, safety instructions, and drainage video
www.myaspira.com/pat_ifu_download.php

For Healthcare Professionals

Product information, video, demonstration kit, and prescription for ordering supplies
www.myaspira.com/clin_kit_demo.php

PleurX[®]

For Patients

Description of the drainage system and frequently asked questions
<http://bit.ly/1oNxMla>

Patient brochure, drainage instruction chart, podcast, and video
<http://bit.ly/1wT2zHp>

For Healthcare Professionals

Product information, drainage system, insertion, billing, and prescription for ordering supplies
<http://bit.ly/1DBG6BM>

Figure 4. Resource Information



Figure 3. PleurX[®] System

Note. Image courtesy of CareFusion Corp. Used with permission.

Malignancy-Related Ascite Management Factors

- Malignancy-related ascites are caused primarily by three conditions: peritoneal carcinomatosis, extensive liver metastases, or a combination of both (Runyon, 2014; Runyon et al., 1992).
- Malignancy-related ascites of advanced cancer carry a poor prognosis and limited lifespan of one to four months, except in untreated ovarian cancer (Ayantunde & Parsons, 2007).
- The serum-ascites albumin gradient (SAAG) is determined by subtracting the albumin level in the ascites from the serum albumin level, both obtained on the same day (Runyon, 2014).
- Low-gradient SAAG associated with peritoneal carcinomatosis is the most common cause, accounting for 53% of malignancy-related ascites, whereas high-gradient SAAG ascites associated with liver metastases and portal hypertension account for 13% of cases (Runyon, Hoefs, & Morgan, 1988).
- Aspira® and PleurX® provide catheters and drainage systems that are safe, easy to use, and demonstrate a low infection rate. They provide education for patients and healthcare profession-

als as well as equipment to perform home drainage and dressing changes.

References

- Ayantunde, A.A., & Parsons, S.L. (2007). Pattern and prognostic factors in patients with malignant ascites: A retrospective study. *Annals of Oncology*, 18, 945–949. doi:10.1093/annonc/mdl49
- Runyon, B.A. (2014). Malignant-related ascites. Retrieved from www.uptodate.com/contents/evaluation-of-adults-with-ascites
- Runyon, B.A., Hoefs, J.C., & Morgan, T.R. (1988). Ascitic fluid analysis in malignancy-related ascites. *Hepatology*, 8, 1104–1109. doi:10.1002/hep.1840080521
- Runyon, B.A., Montano, A.A., Akriviadis, E.A., Antillon, M.R., Irving, M.A., & McHutchison, J.G. (1992). The serum-ascites albumin gradient is superior to the exudat-transudate concept in the differential diagnosis of ascites. *Annals of Internal Medicine*, 117, 177–183. doi:10.7326/0003-4819-117-3-177

can safely perform home drainage. Both drainage systems provide detailed patient instructions and visuals as well as videos to assist in patient education. Figure 4 lists resources for healthcare professionals and patients to assist with education, procurement of supplies, and visual aids. Oncology nurses are responsible for ensuring that patients and caregivers are adequately educated so that they are able to manage the catheter and drainage of ascites at home.

Conclusion

Malignant ascites are a challenge to oncology nurses, patients with cancer, and their caregivers. It is an end-of-life issue that affects quality of life. Peritoneal catheters that allow home drainage of malignant ascites certainly allow the patient to be more comfortable and autonomous with control of a very significant symptom. Aspira and PleurX provide safe and effective systems for this service. The case study provided the impetus for the author's institution to explore better systems and processes to improve the quality of care to patients with malignancy-related ascites.

Anne Marie Flaherty, MSN, RN, APNC, AOCNS®, is an advanced practice nurse in the Gastrointestinal Oncology Division at the John Theurer Cancer Center at Hackensack University Medical Center in New Jersey. No financial relationships to disclose. Mention of specific products and opinions related to those products do not indicate or imply endorsement by the

Oncology Nursing Forum or the Oncology Nursing Society. Flaherty can be reached at aflaherty@HackensackUMC.org, with copy to editor at ONFEditor@ons.org.

References

- Ayantunde, A.A., & Parsons, S.L. (2007). Pattern and prognostic factors in patients with malignant ascites: A retrospective study. *Annals of Oncology*, 18, 945–949. doi:10.1093/annonc/mdl49
- Bard Access Systems. (2012). Aspira® drainage system. Retrieved from http://www.myaspira.com/clin_clinicians.php
- Becker, G., Galandi, D., & Blum, H.E. (2006). Malignant ascites: A systemic review and guidelines for treatment. *European Journal of Cancer*, 42, 589–597.
- Behrendt, R. (2008). Management of malignant ascites: Current treatment options. *Oncology Nursing News*, 2, 1–16.
- Behrendt, R. (2014). Understanding treatment options for patients with pleural effusions and malignant ascites. Retrieved from <https://event.webcasts.com/viewer/event.jsp?ei=1044450>
- CareFusion. (2014). PleurX® resources. Retrieved from <http://bit.ly/1B3QhtD>
- Cavazzoni, E., Bugiantella, W., Graziosi, L., Franceschini, M., & Donini, A. (2013). Malignant ascites: Pathophysiology and treatment. *International Journal of Clinical Oncology*, 18, 1–9.
- Courtney, A., Nemcek, A.A., Rosenberg, S., Tutton, S., Darcy, M., & Gordon, G. (2008). Prospective evaluation of the PleurX catheter when used to treat recurrent ascites associated with malignancy. *Journal of Vascular and Interventional Radiology*, 19, 1723–1731.
- Chung, M., & Kazuch, P. (2008). Treatment

- of malignant ascites. *Current Treatment Options in Oncology*, 9, 215–233.
- Mullard, A.P., Bishop, J.M., & Jibani, M. (2011). Intractable malignant ascites: An alternative management option. *Journal of Palliative Medicine*, 14, 251–253.
- O'Neill, M.J., Weisleder, R., Gervais, D.A., Hahn, P.F., & Mueller, P.R. (2001). Tunneled peritoneal catheter placement under sonographic and fluoroscopic guidance. *American Journal of Roentgenology*, 177, 615–618.
- Rosenthal, D.A. (2009). *Management of malignant ascites*. Retrieved from <http://bit.ly/1yx0q71>
- Runyon, B.A. (2014). Malignant-related ascites. Retrieved from <http://bit.ly/1uhHajz>
- Runyon, B.A., Hoefs, J.C., & Morgan, T.R. (1988). Ascitic fluid analysis in malignancy-related ascites. *Hepatology*, 8, 1104–1109. doi:10.1002/hep.1840080521
- Runyon, B.A., Montano, A.A., Akriviadis, E.A., Antillon, M.R., Irving, M.A., & McHutchison, J.G. (1992). The serum-ascites albumin gradient is superior to the exudat-transudate concept in the differential diagnosis of ascites. *Annals of Internal Medicine*, 117, 177–183.
- Schumacher, D.L., Saclarides, T.J., & Staren, E.D. (1994). Peritoneovenous shunts for palliation of the patient with malignant ascites. *Annals of Surgical Oncology*, 1, 378–381.
- Shuman, L.S. (2008). Tunneled catheter placement in the management of malignant ascites and pleural effusions. *Journal of Lancaster General Hospital*, 3–4, 136–138.
- Tapping, C.R., Ling, L., & Razack, A. (2012). PleurX drain use in the management of malignant ascites. *British Journal of Radiology*, 85, 623–623.