

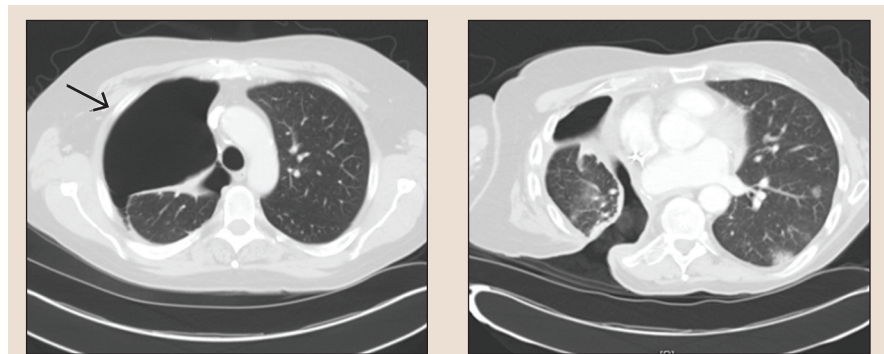
Diagnosis and Management of Postpneumonectomy Empyema With an Eloesser Flap

Victoria Sherry, MSN, CRNP, AOCNP®, Nancy Patton, MSN, RN, OCN®, and Carrie Tompkins Stricker, PhD, CRNP, AOCN®

Postpneumonectomy empyema (PPE) is an uncommon and devastating complication of pneumonectomy, with substantial morbidity and mortality. The condition is characterized by pleural cavity infection and inflammation. This article focuses on the management of complicated and persistent PPE with a procedure called Eloesser flap placement, a type of open-window thoracotomy.

Mr. F, a 61-year-old former smoker, presented to his primary care provider with right rib pain after falling off his bicycle. A chest x-ray incidentally showed consolidation in the right lower lobe. Positron-emission tomography and computed tomography (CT) scan demonstrated a 15 cm fludeoxyglucose avid right lower lung mass and fludeoxyglucose avid right hilar adenopathy. Transbronchial biopsy of the right lower lobe revealed a well-differentiated adenocarcinoma. Mediastinoscopy revealed all mediastinal lymph nodes to be negative for malignancy. Mr. F underwent a right lower lobectomy. Final pathology revealed a 15.5 cm tumor; therefore, he had stage IB non-small cell lung cancer.

Mr. F proceeded with four cycles of adjuvant chemotherapy. A CT scan performed after his chemotherapy and four months postsurgery unexpectedly showed a new right pneumothorax (see Figure 1). He was completely asymptomatic at the time but was admitted to the hospital and a chest tube was placed. Bronchoscopy revealed a bronchopleural fistula at the right lower lobe stump. A bronchopleural fistula is a communication between the pleural space and the large airways of the lungs known as the bronchial tree. The condition is a substantial risk factor for pneumothorax and infection of the associated pleural cavity, given that it provides a pathway of entry for bacterial organisms (Lois & Noppen, 2005). Surgical oncology was consulted



Note. The computed tomography scan at left shows a right pneumothorax before Eloesser flap placement. The scan at right demonstrates right posterior 8th, 9th, and 10th rib thoracotomies with right posterior chest wall defect communicating with the right pleural cavity after Eloesser flap placement.

Figure 1. Chest Scan Before and After Eloesser Flap Placement

Note. Images courtesy of the University of Pennsylvania Health System. Used with permission.

but recommended deferring intervention because Mr. F remained asymptomatic.

Nine months later, Mr. F became symptomatic with dyspnea on exertion, productive cough, and wheezing. He presented to

the emergency department in respiratory distress with a fever of 102°F and cough productive of foul-smelling thick, brown sputum. A CT scan showed an air-fluid level within the pleural space consistent with

Victoria Sherry, MSN, CRNP, AOCNP®, is an oncology nurse practitioner in thoracic malignancies at the Abramson Cancer Center and a faculty member in the Oncology Minor/Post-Master's Certificate Program in the School of Nursing, both at the University of Pennsylvania in Philadelphia; Nancy Patton, MSN, RN, OCN®, is a staff RN at Bryn Mawr Hospital in Pennsylvania; and Carrie Tompkins Stricker, PhD, CRNP, AOCN®, is the director of Clinical Programs and an oncology nurse practitioner in the LIVESTRONG® Survivorship Center of Excellence in the Abramson Cancer Center and a clinical assistant professor in the School of Nursing, both at the University of Pennsylvania.

Digital Object Identifier: 10.1188/10.CJON.553-556