

Restoring Patency to Central Venous Access Devices

**Cynthia Cummings-Winfield, BScN, CON(C),
and Tayreez Mushani-Kanji, RN, BScN, CON(C), CHPCN(C)**

In September 2006, the Oncology Nursing Advisory Board met to discuss the current management of central venous access device (CVAD) occlusions for patients receiving cancer treatment in centers across Canada. The board found inconsistency in practice across the country and advocated for the development of evidence-based, standardized guidelines for the use of thrombolytic agents to clear thrombotic occlusions. PubMed was searched for articles related to catheter occlusion, catheter patency, and catheter complications published from 1997–2007. The board compared institutional and published protocols for thrombolytic treatment of occluded CVADs, in light of a systematic, evidence-based review of the literature on CVAD-related complications. Restoration of CVAD patency, when appropriate, represents a safe, effective, and cost-effective alternative to device replacement and improves patient quality of life. The treatment algorithm presented in this article reflects the board's consensus recommendations for managing thrombotic CVAD occlusions in adult patients with cancer.

Access to venous circulation is critical for many patients with cancer. Treatment regimens can be complicated, often requiring repeated and reliable venous access. In oncology practice, the most common indication for placing a central venous access device (CVAD) is the delivery of chemotherapeutic medications. However, the same device may be used for the administration of supportive therapies (e.g., antibiotics, antiemetics), blood products, and nutritional supplementation (Wingerter, 2003). CVADs also may be used for withdrawal of blood samples (Wingerter).

Medications and nutrients instilled directly through wide-bore catheters into the superior vena cava can be delivered more efficiently and in larger volumes than would be possible via the peripheral circulation. Fluids instilled into the major veins become diluted rapidly as they emerge from the catheter lumen. This allows for safe and comfortable administration of concentrated solutions, vesicants, or irritants without pain or damage to the vessel wall and with minimal risk of extravasation and chemical phlebitis (Dudrick, 2006). However, CVADs have the potential for complications such as thrombotic occlusion, which can lead to treatment delays and affect patient quality of life (Moureau, Poole, Murdock, Gray, & Semba, 2002).

Patients With Cancer and Central Venous Access Devices

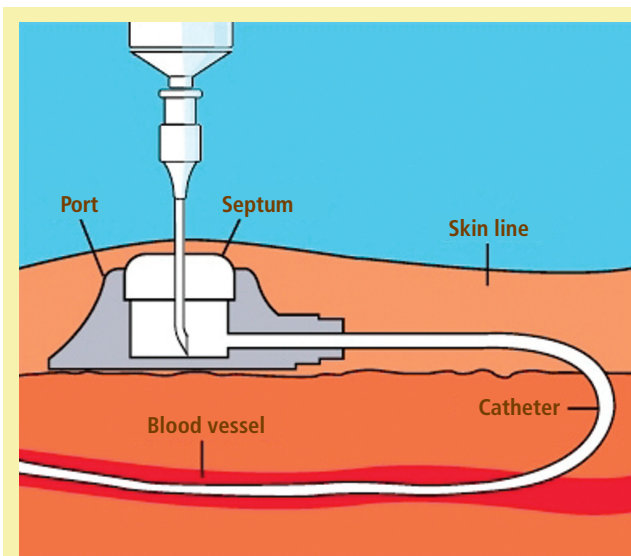
According to the World Health Organization, cancer prevalence is increasing globally, and cancer now is classified under

At a Glance

- ◆ Central venous access is critical for many patients with cancer for delivery of treatment and supportive care.
- ◆ Replacing dysfunctional central venous access devices (CVAD) is expensive and invasive; therefore, steps to prevent or resolve thrombotic occlusions are essential.
- ◆ Evidence-based guidelines for managing thrombotic CVAD occlusions support oncology nursing practice, promote positive patient outcomes, and reduce costs associated with device replacement.

Cynthia Cummings-Winfield, BScN, CON(C), is the coordinator for nursing research and professional practice development, and Tayreez Mushani-Kanji, RN, BScN, CON(C), CHPCN(C), is a staff development instructor, both at Cross Cancer Institute in Edmonton, Canada. The authors gratefully acknowledge Hoffman La-Roche Ltd., manufacturers of Alteplase/Cathflo®. The company's support was instrumental in identifying clinical leaders in oncology to develop these guidelines and for securing John Ashkenas, PhD, Script Medical Writing, to assist in manuscript development. Mention of specific products and opinions related to those products do not indicate or imply endorsement by the *Clinical Journal of Oncology Nursing* or the Oncology Nursing Society. (Submitted July 2008. Accepted for publication July 23, 2008.)

Digital Object Identifier:10.1188/08.CJON.925-934



Note. Implanted ports are placed subcutaneously, often within the anterior chest wall. The operation can be performed under local anesthesia. Implanted ports are accessed via a special noncoring (Huber-type) needle. The catheter enters the venous system as shown, commonly through the subclavian vein. As in other central venous access devices, the catheter tip resides in the superior vena cava.

Figure 1. Accessing Ports

Note. Image courtesy of Bard Access Systems, Inc. Used with permission.

the framework of chronic diseases (Cancer Care Ontario, 2007; Grunfeld, 2006). Given the complexity and intensity of cancer treatment, long-term central vascular access is a priority for an increasing number of patients. Indeed, an estimated five million CVADs are placed every year in the United States alone (Maki, Stolz, Wheeler, & Mermel, 1997). Although that statistic includes other patient groups that require long-term venous access (e.g., individuals with renal failure requiring hemodialysis), the number of patients with cancer with CVADs is undoubtedly large.

CVADs are inserted with the expectation that they will function until the need for central venous access has passed. Some classes of CVAD can be expected to last more than 18 months (Galloway & Bodenham, 2004); however, many devices are removed prematurely because of a variety of common complications (Galloway & Bodenham).

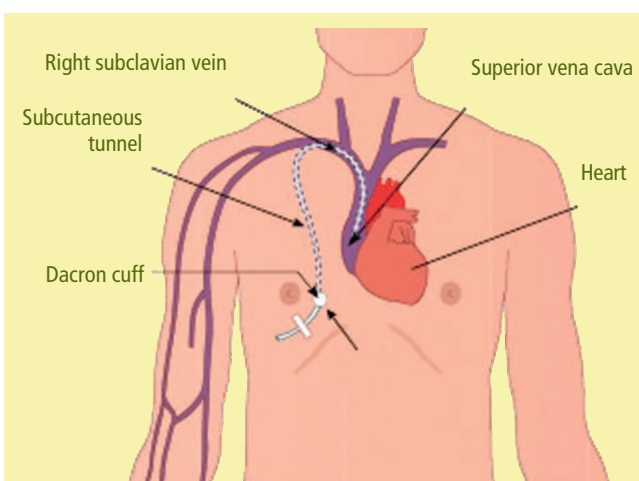
Replacing a dysfunctional CVAD is an expensive and, in many cases, invasive procedure with some inherent risk to the patient. Replacement usually requires a new venous access site and may necessitate surgical or radiologic consultation and sedation, as well as the risk of complications associated with central venous cannulation (Jacobs, Haygood, & Hingl, 2001). Salvaging a device may be quicker than replacing it and may avoid delays in treatment. The cost of device replacement (estimated at \$850–\$1,500, depending in part on the type of CVAD) greatly exceeds that of salvage (Kokotis, 2005). Although the cost of salvage can encompass chair time, a declotting agent, and nursing time, those things intuitively pale in comparison to the cost of replacing a CVAD, which can include interventional radiology time, diagnostic imaging, nursing time, and the price of a new

access device. In addition to financial costs, catheter replacement can pose a clinical risk and affect patients' quality of life. Therefore, nurses and physicians should take appropriate steps to prevent CVAD complications and to salvage dysfunctional CVADs when possible. In particular, thrombolytic treatment is recommended for restoring the patency of devices occluded by fibrin or blood clots.

Selection of a Central Venous Access Device

CVADs all share a common characteristic of terminating in the distal third of the superior vena cava. The devices fall into multiple categories, distinguished by whether they allow one or more solutions to be administered separately (single-, double-, or multiple-lumen catheters) and by other aspects of their designs that determine how and where they are inserted into the venous circulation and how the devices are used. For instance, catheters, which allow for external access through one or more exposed lumens, should be distinguished from ports, which are implanted under the skin and must be accessed via a special noncoring needle. The type of CVAD used should be chosen based on a variety of considerations, including prescribed therapy, duration of therapy, physical assessment, patient health history, support system and resources, device availability, and patient preference (Registered Nurses Association of Ontario [RNAO], 2004).

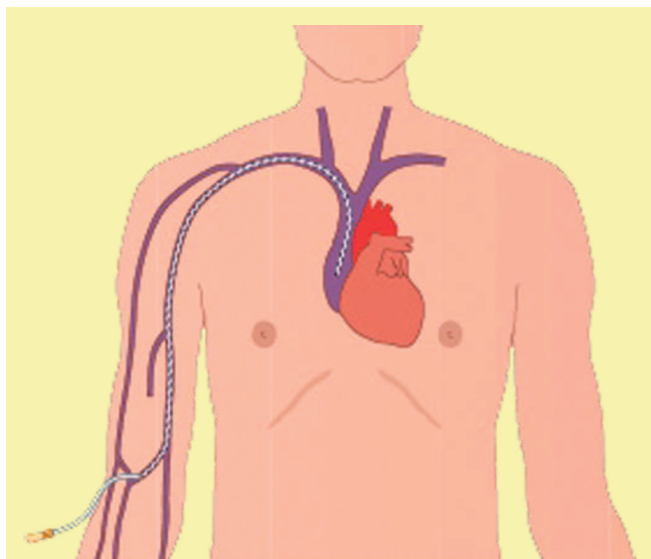
CVADs used in oncology include implanted ports and nonimplanted catheters. The latter group of devices includes central venous catheters, which usually are tunneled through subcutaneous tissue, and peripherally inserted central catheters (PICCs), which are inserted into the major veins of the arm (Galloway & Bodenham, 2004).



Note. The catheter tip resides at the junction of the superior vena cava and the right atrium.

Figure 2. Placement of Central Venous Access Devices

Note. From "Complications Associated With Venous Access Devices: Part One," by H. Hamilton, 2006, *Nursing Standard*, 20(26), p. 44. Copyright 2006 by Clinical Skills Ltd. Reprinted with permission.



Note. Peripherally inserted central catheters commonly are placed through one of the major veins of the arm (the cephalic, basilic, or median cubital veins), with the catheter tip residing in the superior vena cava.

Figure 3. Placement of Peripherally Inserted Central Catheters

Note. From "Complications Associated With Venous Access Devices: Part One," by H. Hamilton, 2006, *Nursing Standard*, 20(26), p. 44. Copyright 2006 by Clinical Skills Ltd. Reprinted with permission.

Implanted Ports

Implanted ports consist of a fluid reservoir with a puncturable septum implanted subcutaneously (see Figure 1) and are best suited to long-term therapy (Galloway & Bodenham, 2004). The devices require surgical or radiologic placement and removal.

Nonimplanted Central Venous Access Devices

Nonimplanted CVADs may be tunneled or nontunneled. Tunneled CVADs (see Figure 2) are placed through subcutaneous tissue, with an exit site on the chest or abdominal wall and the tip resting in the superior vena cava (RNAO, 2004). The device contains a dacron cuff, which allows for stabilization of the catheter in the subcutaneous tissue and prevents superficial infection (Galloway & Bodenham, 2004). Such catheters require surgical or radiologic insertion, typically into the jugular or subclavian vein or inferior vena cava, and are appropriate for longer-term therapy.

Nontunneled CVADs (PICCs) typically are placed via the cephalic, basilic, or median cubital veins, sparing other sites of venous access (Galloway & Bodenham, 2004) (see Figure 3). PICCs are the least invasive of all CVADs but contain a narrow lumen, which is associated with a greater risk of occlusion than other CVADs. PICCs are associated with a relatively low risk of infection (RNAO, 2004).

Complications Related to Central Venous Access Devices

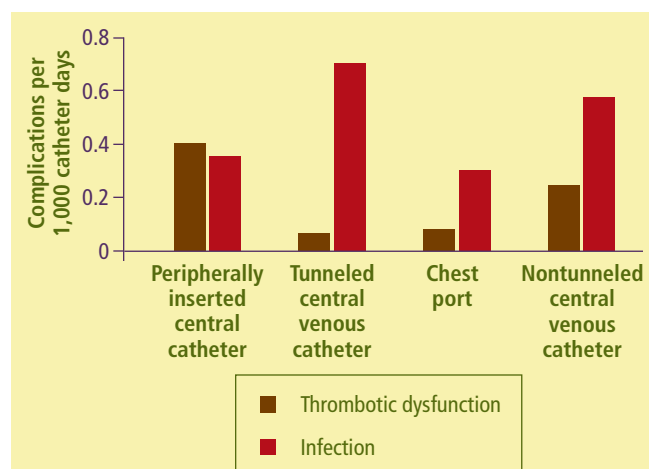
Numerous complications can arise directly from central vein cannulation; however, the incidence of such complications

is difficult to ascertain. Acute complications include pneumothorax, hemothorax, embolization, and cardiac tamponade. Healthcare professionals must recognize such complications by their signs and symptoms and take necessary action, should they occur.

Common complications associated with CVADs include, but are not limited to, infection at the insertion site or within the bloodstream (bacteremia or sepsis, the most severe complication), phlebitis (mechanical or chemical), or extravasation (Hamilton, 2006a). Mechanical obstruction may occur, including pinch-off syndrome, in which the catheter tunneled between the first rib and the clavicle becomes compressed between those bones or the catheter kinks or is improperly positioned (Galloway & Bodenham, 2004; Jacobs, 2003; Kerner, Garcia-Careaga, Fisher, & Poole, 2006). In addition, the device itself may malfunction or be obstructed by a retaining suture that is too tight.

Catheter occlusion can result from extraluminal or intraluminal complications. Extraluminal complications include persistent withdrawal occlusion such that infusion of solutions is possible but aspiration of blood is not possible because of a fibrin sheath. Sluggish infusion of solution and sluggish withdrawal of blood may be caused by an extraluminal fibrin tail. In addition, a mural thrombus can form when fibrin from the injured vessel wall binds to fibrin covering the catheter surface (Forauer & Theoharis, 2003). Intraluminal occlusions may be the result of drug precipitates when incompatible medications are infused through the same catheter lumen without proper flushing. Lipid residues also can build up in an internal catheter lumen. Finally, intraluminal thrombotic occlusions can occur.

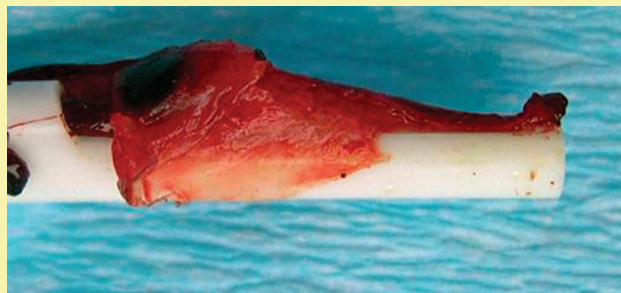
A large-scale study analyzed complications of CVADs used for outpatient home infusion therapy in patients with varying diagnoses, including a small percentage of patients with cancer. Among approximately 50,000 patients (> 2.5 million catheter days), the most common complication observed was loss of



Note. The study population included a small percentage of patients with cancer.

Figure 4. A Large-Scale Analysis of Central Venous Access Device Complications in Individuals Receiving Central Infusions on an Outpatient Basis

Note. Based on information from Moureau et al., 2002.



Note. Fibrin begins to accumulate on the external surface shortly after a central venous access device is inserted. When insoluble fibrin deposits form as a sheath near the catheter tip, they can block the flow of medications into the vein (Jacobs, 2003). An extension of this sheath (the fibrin tail seen in the image above) can block withdrawal of blood through the catheter, creating a ball-valve effect.

Figure 5. A Fibrin Sheath With a Tail

Note. Image courtesy of Joy Blacka, RN, of Bard Access Systems, Inc. Used with permission.

patency (CVAD dysfunction from blockage). In particular, nonthrombotic blockage was the single most common cause of loss of patency observed (Moureau et al., 2002), followed by thrombotic blockage and infection. However, not all kinds of CVADs were at equal risk of the different complications. For instance, tunneled CVADs were at relatively high risk of infection but low risk of thrombosis compared with PICCs (Moureau et al.) (see Figure 4).

Astute nursing assessment strategies are required to determine the probable causes of CVAD complications. Once a nurse has identified the cause, he or she must take appropriate actions to salvage venous access. If mechanical and chemical causes are ruled out, empirical treatment with a thrombolytic agent should be attempted. Published guidelines from the Oncology Nursing Society (2004) and the RNAO (2005) support the practice of early intervention to troubleshoot and resolve CVAD occlusions. The guidelines presented in this article are directed specifically at the management of thrombotic occlusions in CVADs.

Causes and Consequences of Thrombotic Occlusions

Thrombotic occlusions occur when blood or blood elements accumulate within, surrounding, or at the tip of catheters (Jacobs, 2003). Patients may be at heightened risk of thrombosis because of hypercoagulability because of “tumor cell activation of clotting, vessel wall injury, and stasis” (Prandoni, Piccioli, & Griolami, 1999, p. 437) or because of their chemotherapeutic regimens (Jacobs). As well, blood may reflux into a catheter tip as a result of changes in intrathoracic pressure during violent sneezing, coughing, or vomiting (Wingerter, 2003). However, in many cases, CVAD occlusion can be attributed directly to poor infusion technique, specifically to failure to flush lines properly or to use a locking solution appropriate to the device. Incorrect procedure when disconnecting a positive or negative displacement device from a line can have the same effect (Hadaway, 2005).


After blood withdrawal, a CVAD must not be allowed to stand without fluid flow or minimal infusion rates (keep the vein open) (Wingerter, 2003) but must be actively flushed with a solution such as 0.9% saline. Push-pause instillation, involving frequent stopping-starting of the flushing solution, should be used to create turbulent flow within the line (Hamilton, 2006b; RNAO, 2005).

In general, thrombi can cause three distinct forms of occlusion that impair fluid instillation, withdrawal, or both. In a withdrawal (ball-valve) occlusion, fluids can be instilled but blood cannot be withdrawn without resistance. Withdrawal occlusions occur because of insoluble proteins (thrombi or fibrin tails) extending from the catheter tip (see Figure 5). They are pulled over and cover the catheter tip as blood flows into the catheter—a so-called ball-valve effect. Partial or incomplete occlusion results in sluggish instillation or withdrawal of blood. A complete catheter occlusion restricts fluid instillation and blood withdrawal. Figure 6 shows different classes of thrombotic occlusion.

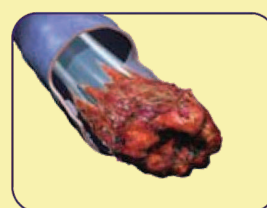Finally, thrombotic material can accumulate inside a port to create a so-called reverse ball-valve effect, blocking instillation while allowing withdrawal.

Safety and Efficacy of Thrombolytic Treatment

The first report showing that a thrombolytic agent could be used to clear an occluded CVAD (Hurtubise, Bottino, Lawson, & McCredie, 1980) employed streptokinase, an enzyme that is



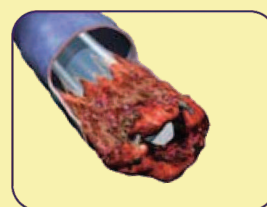Intraluminal thrombus



Fibrin sheath



Fibrin tail

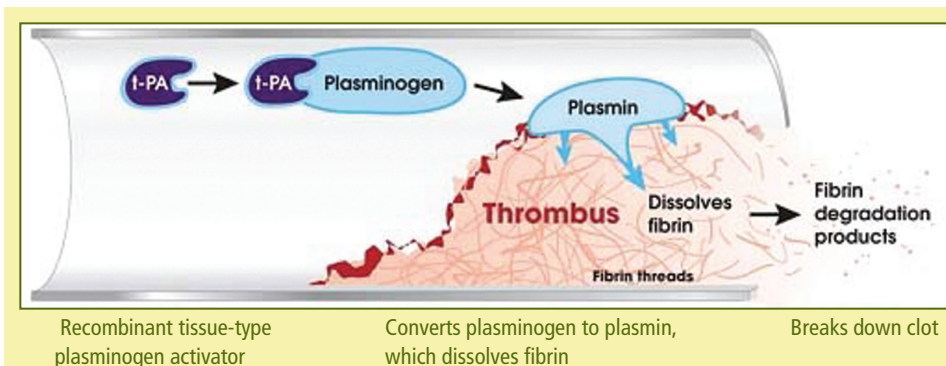


Mural thrombus

Note. Fibrin deposits, as well as fully formed thrombi, can produce a plug residing within the lumen of a catheter (an intraluminal thrombus) or can form a sock-like sheath that covers the exterior of the catheter tip. The insoluble material can also form a “tail” at the catheter tip, interfering with blood withdrawal. Thrombi forming along the wall of the vein but exterior to the catheter (mural thrombi) also can interfere with fluid flow through the central venous access device.

Figure 6. Classes of Thrombotic Occlusion

Note. Images courtesy of Genentech, Inc. Used with permission.



Note. Alteplase is a recombinant form of the normal blood component tissue-type plasminogen activator (t-PA), which causes thrombolysis as shown here. t-PA binds to and activates plasminogen, producing plasmin. Plasmin cleaves fibrin, releasing fibrin degradation products and causing the clot to dissolve.

Figure 7. Degradation of an Intraluminal Blood Clot (Thrombolysis)

Note. Image courtesy of Genentech, Inc. Used with permission.

and intracranial hemorrhage are not anticipated. In clinical trials of adult and pediatric patients, no such events have been attributed to alteplase treatment (Blaney et al., 2006; Deitcher et al., 2002). Two cases of major hemorrhage were observed but were not considered to be related to t-PA treatment (Deitcher et al.). Alteplase has not been studied in patients known to be at risk for bleeding.

Therefore, alteplase should be used with caution in patients with known or suspected CVAD infection. In situ decontamination of CVADs has been reported, but device removal should be considered when evidence of CVAD-related infection exists, particularly

no longer widely used for that purpose (Valji, 2000). For some time, urokinase-type plasminogen activator (u-PA) became the standard of care for that indication. Because of concerns about possible contaminating pathogens in the u-PA available at the time, however, the agent was withdrawn from the market in 1999 (Valji). In its place, clinics now use a different recombinant enzyme, tissue-type plasminogen activator (t-PA, or alteplase, marketed for that purpose as Cathflo® Activase® [Genentech, Inc.]). Unlike the other agents, t-PA binds avidly and specifically to fibrin, one of the major components of a blood clot. t-PA causes thrombolysis by activating plasminogen (present in the circulation and the clot) to generate plasmin, which breaks apart the fibrin protein, thus dissolving the clot (see Figure 7). Anticoagulant agents such as heparin are ineffective against existing clots and cannot be used to restore patency to occluded CVADs (Fedan, 2003).

Clinical Evidence

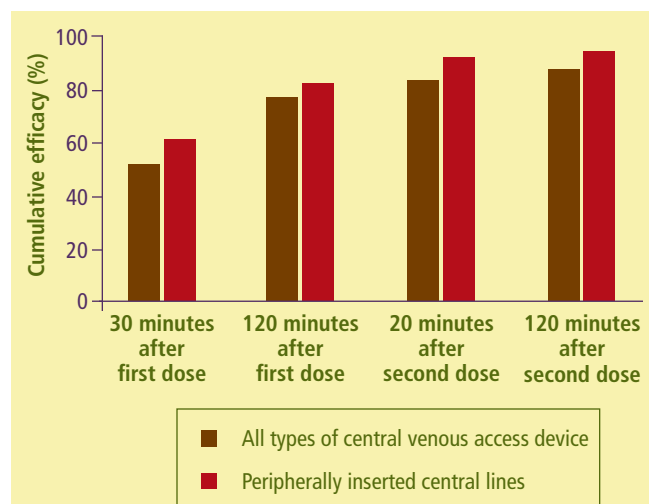
In a head-to-head trial, t-PA (alteplase) was shown to be more effective at clearing thrombotic occlusions than nonrecombinant u-PA (Haire, Atkinson, Stephens, & Kotulak, 1994). A newer, recombinant form of u-PA (Abbokinase®, Microbix Biosystems Inc.) has been developed and is expected to be similar to the nonrecombinant form but without the potential contamination risks (Haire et al., 2004). Other agents that could be used for that purpose are being studied (Liu, Jain, Shields, & Heilbrun, 2004; Moll et al., 2006). Alteplase is approved in Canada and the United States for restoring CVAD patency (Genentech, Inc., 2003). Therefore, all recommendations for thrombolytic treatment in this article relate to alteplase.

Safety of Alteplase Treatment of Occluded Central Venous Access Devices

When alteplase is used for CVAD clearance (as with Cathflo), the concentration in the circulation does not reach pharmacologic levels. Any alteplase released into the circulation is metabolized rapidly by the liver (plasma half-life less than five minutes). Therefore, systemic complications such as bleeding

Staphylococcus aureus bacteremia or candidemia (Galloway & Bodenham, 2004).

Alteplase should be used with caution in patients with thrombocytopenia, other hemostatic defects, or any condition for which bleeding constitutes a significant hazard or would be particularly difficult to manage, as well as with patients who are at high risk for embolic complications. Caution should be exercised with patients who have active internal bleeding or who have had any of the following within 48 hours: surgery, obstetrical delivery, percutaneous biopsy of viscera or deep tissues, or puncture of noncompressible vessels (Middleton & Ruzevick, 2004). Alteplase is contraindicated in patients with known hypersensitivity to the drug or any component of its formulation (e.g., alteplase, L-arginine, phosphoric acid, polysorbate-80) (Genentech, Inc., 2003).



Note. In the Cardiovascular Thrombolytic to Open Occluded Lines-2 Trial, one to two standard doses of alteplase were used to restore patency to occluded peripherally inserted central lines and other types of central venous access devices.

Figure 8. Efficacy of Alteplase Treatment

Note. Based on information from Deitcher et al., 2002; Ng et al., 2004.

Efficacy in Central Venous Access Device Clearance

The efficacy of alteplase in clearing occluded CVADs has been reported to be 87%–90% (Deitcher et al., 2002; Journey-cake & Buchanan, 2006; Ponc et al., 2001). In the various efficacy studies, treatment was applied as many as two times, for one to two hours at each application. The largest of the studies was the Cardiovascular Thrombolytic to Open Occluded Lines–2 (COOL-2) interventional trial (N = 995), which showed 87% efficacy (Deitcher et al.). A subanalysis of the COOL-2 data focusing on the 242 patients with PICCs showed still higher levels of treatment success—93% on a cumulative basis when treated as many as two times (see Figure 8) (Ng, Li, Tu, & Semba, 2004).

The published clinical trials with alteplase have excluded patients with complete CVAD occlusions, when instilling the specified volume of fluid to treat the occlusion was not possible. However, a recent trial of recombinant u-PA has been reported in which totally occluded lines were treated successfully with a variation on the normal CVAD instillation procedure (Haire et al., 2004; Horne, 2004; Kerner et al., 2006). The alternate procedure, requiring a three-way stopcock, is used widely in infusion clinics and has been described extensively (Hamilton,

2006b; Infusion Nurses Society, 2006; Ottawa Hospital, 2006). The standard instillation method (for partial occlusions) and alternate (stopcock) method (for total occlusions) are described in Figures 9 and 10.

Restoration of Patency

Institutional Protocols for Treatment of Thrombotic Occlusions

Depending on institutional policies, RNs may require competency validation to manage occluded CVADs. Institutional policies also direct whether a physician's order or a medical directive is required to proceed with a CVAD clearance protocol. An institutional protocol should outline the procedure for the number of instillations and dwell times and whether diagnostic imaging is required.

Reconstituting Alteplase

Alteplase is provided in sterile vials and must be reconstituted immediately before use. When stored at 2°C–30°C (36°F–86°F), it may be used for intracatheter instillation within

This procedure is to be used when a central venous access device (CVAD) can be instilled directly with fluid. If a blockage does not allow you to introduce at least 2 ml of fluid from a syringe, use the alternate (stopcock) protocol (see Figure 10).

1. Set aside the following materials.

- Gloves
- Sterile gauze pad
- 3 x 10–12 ml Luer lock syringes, one filled with 2 ml sterile 0.9% NaCl
- Antiseptic swabs per institutional recommendation
- 2 x 10–12 ml syringes filled with sterile 0.9% NaCl
- 10–12 ml syringe filled with appropriate amount and type of locking solution, if needed
- Alteplase vial supplied by pharmacy
- Medication label
- Sterile water—10 ml vial
- Positive pressure device (PPD) or appropriate cap, if needed

2. Explain procedure to patient.

3. Perform hand hygiene.

4. Reconstitute alteplase (see above) and aspirate into 10–12 ml syringe.

5. Don protective gloves.

6. Clean connection between catheter and cap using aseptic technique.

7. Attach syringe with alteplase to the catheter end.

8. Unclamp the catheter (unless using a clampless device).

9. Instill the alteplase solution gently and slowly.

10. Reclamp the catheter (unless using a clampless device) and ensure the syringe is secured to the catheter during dwell time.

11. Place a medication label on the catheter, stating, "Dec clotting agent in place. DO NOT USE."

Allow alteplase to dwell in the CVAD for 30 or 120 minutes before checking CVAD patency. Note that the probability of success is decreased with a shorter dwell time.

If clinically appropriate and permitted by institutional policy, a well-secured syringe may be left attached to the end of the catheter during dwell time.

Evaluating Patency

To check CVAD patency, remove cap and attempt to aspirate dec clotting agent and blood using an empty 10 ml syringe.

If you can withdraw blood without resistance (3 ml in three seconds):

- Withdraw the dec clotting agent and 4–5 ml of blood into a 10–12 ml syringe.
- Flush the CVAD with 20 ml of sterile 0.9% NaCl using turbulent flow to clear it of any remaining blood.
- Connect to IV tubing or lock the CVAD with appropriate locking solution.

If you cannot aspirate blood or you experience resistance:

- Reinstill the original dose and allow alteplase to dwell for an additional 90 minutes (for a total of 120 minutes).
- If you are still unable to aspirate blood, repeat procedure with second instillation of alteplase, checking patency again after 30 minutes. If necessary, reconstitute the second dose, allowing alteplase to dwell for 90 minutes or overnight, depending on institute procedure.
- If you are still unable to aspirate blood after the second instillation of alteplase and an overnight dwell, notify the physician.

Ensure catheter or extension tubing is clamped and injection cap or dead-end cap is secure and labeled while alteplase treatment is ongoing.

Document the procedure, including the amount of alteplase used, confirmation of occlusion by x-ray, dwell time(s), number of lumens, outcome of the procedure, patient teaching, and how patient tolerated the procedure.

Figure 9. Standard Protocol for Treating Incomplete or Withdrawal Occlusions in Central Venous Access Devices

This procedure is to be used when the CVAD cannot be instilled directly with fluid. If you are able to introduce at least 2 ml of fluid from a syringe into the line, use the standard protocol (see Figure 9).

1. Set aside the following materials.
 - Gloves
 - Sterile gauze pad
 - 3 x 10–12 ml Luer lock syringes, one filled with 2 ml sterile 0.9% NaCl
 - Antiseptic swabs per institutional recommendation
 - 2 x 10 ml syringes filled with sterile 0.9% NaCl
 - Positive pressure device (PPD)
 - 10–12 ml syringe filled with appropriate amount and type of locking solution
 - Alteplase vial supplied by pharmacy
 - Medication label
 - Sterile water—10 ml vial
 - Sterile three-way stopcock
2. Explain procedure to patient.
3. Perform hand hygiene.
4. Reconstitute alteplase (see above) and aspirate into 10–12 ml syringe.
5. Don protective gloves.
6. Instill alteplase into the line using the following procedure.
 3. Attach the syringe containing the alteplase to one of the ports on the stopcock.
 4. Attach the empty 10–12 ml syringe to the remaining port on the stopcock.
 5. Turn the stopcock OFF to the syringe containing the alteplase.
 6. Gently aspirate the catheter until the plunger of the 10–12 ml syringe is pulled back to the 3–5 ml mark. Clamp while maintaining negative pressure.
 7. Turn the stopcock OFF to the aspirated syringe.
 8. Unclamp the catheter, or, if using a clampless device, turn stopcock to allow the alteplase to be drawn into the central line.
 9. Once the alteplase is drawn into the catheter, turn the stopcock to close the flow. Clamp catheter (unless using a clampless device) and attach to a PPD.
 10. Place a medication label on the catheter, stating, “Dec clotting agent in place. DO NOT USE.” Allow alteplase to dwell in the catheter for 30 or 120 minutes before checking CVAD patency. Note that the probability of success is decreased with a shorter dwell time. Proceed with all remaining steps in the standard procedure following “Evaluating Patency.”

Using negative pressure to instill alteplase into a fully blocked line (see Figure 11)

1. Clamp central line (unless using a clampless device).
2. Remove PPD and attach the Luer lock end of the three-way stopcock to the catheter, making sure the stopcock is in the OFF position.

Repeat instillations can be carried out using the stopcock procedure described above. If the CVAD remains partially occluded but can now be instilled directly using a syringe, it is not necessary to use the stopcock method.

Figure 10. Alternate (Stopcock) Protocol for Treating Complete Occlusions in Central Venous Access Devices

eight hours of reconstitution. To reconstitute Cathflo, inject 2.2 ml of sterile water for injection, USP, into the vial, directing the diluent stream into the alteplase powder. Slight foaming is not unusual. Let the vial stand undisturbed to allow large bubbles to dissipate. Mix by gently swirling until the contents are completely dissolved. Complete dissolution should occur within three minutes. Do not shake. The reconstituted preparation results in a colorless to pale yellow transparent solution containing 1 mg/ml alteplase at a pH of approximately 7.3 (Genentech, Inc., 2003).

Instillation Procedure

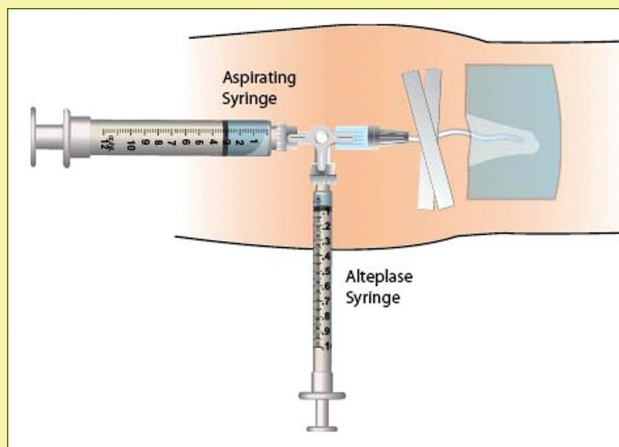
In adult patients, as much as 2 ml of the reconstituted alteplase should be instilled per occluded catheter lumen. However, ascertaining the fill volume for the particular CVAD requiring alteplase instillation is essential. The appropriate method for instillation should be determined by whether the CVAD is partially or completely occluded. For an incomplete occlusion, follow the standard protocol for treating incomplete or withdrawal occlusions (see Figure 9). In the case of a complete catheter occlusion, follow the alternate (stopcock) protocol (see Figures 10 and 11).

Figure 12 presents an algorithm for restoring CVAD patency. The procedure is technically simpler as well as more effective if applied before a CVAD is fully occluded (Shen et al., 2003). Clots that persist for more than seven days become relatively resistant to thrombolytic treatment (Steiger, 2006). Therefore, thrombotic occlusions should be treated as soon as they are identified.

Introducing Standardized Procedures to an Oncology Practice

Institutions are encouraged to adopt these guidelines for managing thrombotic CVAD occlusions. Implementing new clinical practice guidelines can be complex, in part because of the number of multidisciplinary groups that may be affected in a particular practice setting (RNAO, 2002). In general, the process requires commitment at multiple levels within an institution to establish “buy-in” from administrators and patient educators, as well as nurses and physicians in different clinical practice groups. The range of existing practices must be determined, along with the educational and skill-development needs of team members, followed by the design of appropriate educational materials and training to support the integration of clinical practice guidelines. The authors suggest evaluating parameters of change resulting from implementation of clinical practice guidelines, including quality of patient care, patient satisfaction, nursing satisfaction, and cost of care.

Evaluation of clinical practice guidelines should be based on objective, quantifiable measures when possible. Thus, in a review of the effects of implementing the guidelines discussed in this article, changes from baseline should be determined for the number of partial and complete CVAD occlusions, thrombolytic agent dwell time, the number and severity of CVAD-related infections, the number and type of CVADs replaced or removed prematurely, the number of consultations with staff pharmacists, nursing time and costs related to materials, and



Note. Connect a three-way stopcock to the catheter using aseptic technique (see protocol). Connect a 10–12 ml Luer lock syringe (aspirating syringe) to one of the free ports and a smaller syringe containing the thrombolytic agent (alteplase syringe) to the remaining port. With the stopcock set so that the alteplase syringe is off, withdraw the plunger of the aspirating syringe to the 3–5 ml mark. Turn stopcock so that the aspirating syringe is off. Gently instill the thrombolytic agent into the catheter from the alteplase syringe.

Figure 11. Infusing Alteplase Into Occluded Lines Using the Alternative (Stopcock) Method

surgery and clinical consultation time. The outcomes should be revisited at regular intervals as infusion nursing practices evolve.

Implications for Nursing Practice

Nurses require astute assessment skills and sound clinical judgment to identify and successfully manage CVAD complications. They are in a unique position to advocate for and adopt into practice evidence-based clinical practice guidelines to support the management of CVADs. As members of a multidisciplinary team, nurses are important links in the chain of patient care. Economic exigencies, the current nursing shortage, the chronicity of cancer, and the ever-increasing complexity of treatment are driving forces that compel nurses to develop in-depth knowledge of CVAD management. Positive patient outcomes are demonstrated by completion of therapy free of complications and patient satisfaction with care (RNAO, 2005). Table 1 provides a summary of recommendations regarding CVAD occlusions.

Conclusion

Central venous access is crucial to the delivery of cancer therapy. Proper assessment, use, and maintenance of CVADs prevent treatment delays, as well as potentially life-threatening complications. Restoration of CVAD patency, when appropriate, represents a cost-effective alternative to device replacement and improves patient quality of life. Thrombotic occlusion, a common complication of CVAD use, can be resolved safely and effectively with the thrombolytic treatment procedures described

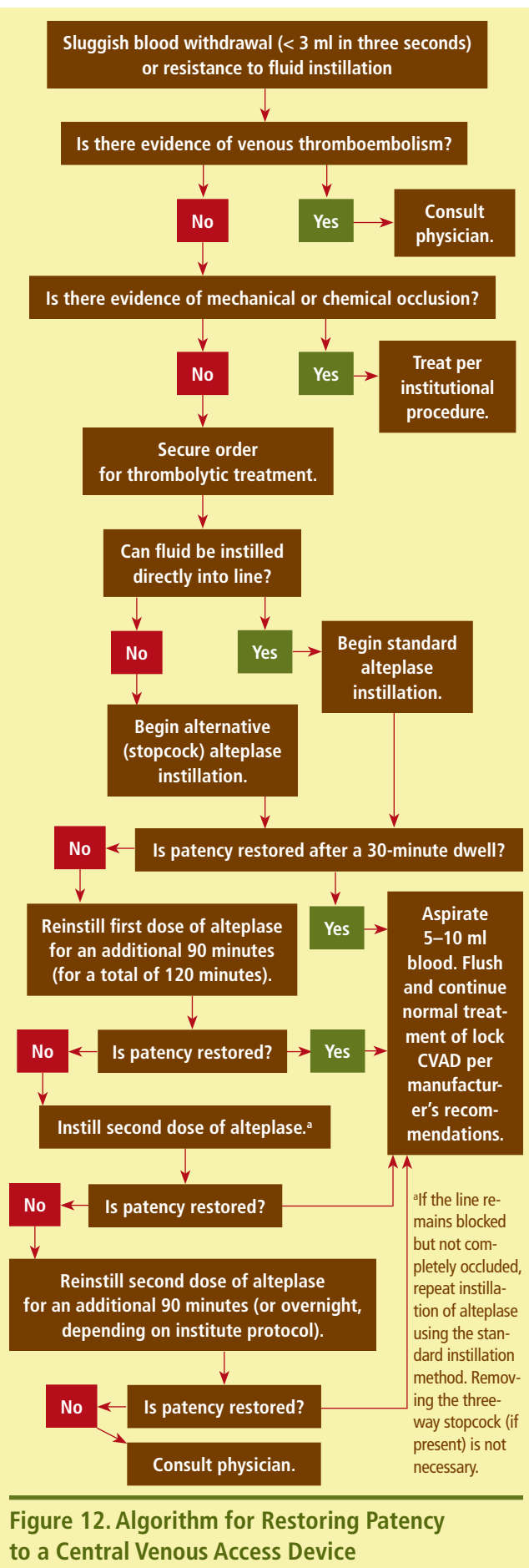


Figure 12. Algorithm for Restoring Patency to a Central Venous Access Device

Table 1. Summary of Recommendations

RECOMMENDATION	LEVEL OF EVIDENCE
Take appropriate steps to prevent central venous access device (CVAD) occlusion and to salvage dysfunctional CVADs. Attempt thrombolytic treatment to restore the patency of devices occluded by blood clots. Apply thrombolytic treatment with caution in patients with known or suspected CVAD infection.	II: strong evidence from at least one properly designed, randomized, controlled trial of appropriate size
Use locking solution or positive pressure device, as directed by device manufacturer, to prevent thrombotic occlusions. Apply thrombolytic treatment as soon as possible after complete or partial thrombotic occlusion has been identified (may require diagnostic imaging).	III: evidence from well-designed trials such as nonrandomized trials, cohort studies, time series, or matched case-controlled studies
Select CVAD type based on expected duration of therapy and the least invasive procedure available. Before attempting thrombolytic treatment, review record and, if necessary, consult with pharmacy to identify possible chemical blockage and determine appropriate clearing solution. Use turbulent flow while flushing lines properly to prevent thrombotic occlusions. Attempt thrombolytic treatment on an empirical basis if no mechanical or chemical causes of CVAD dysfunction can be identified. Apply thrombolytic treatment with caution in patients with active internal bleeding, recent surgery, or hemostatic abnormalities.	V: opinions of respected authorities, based on clinical evidence, descriptive studies, or reports of expert committees

in this article. The procedures, based on best clinical evidence, should be standardized in oncology practice so that they can be implemented consistently and evaluated regularly at all centers where CVADs are used.

Author Contact: Cynthia Cummings-Winfield, BScN, CON(C), can be reached at cindywin@cancerboard.ab.ca, with copy to editor at CJONEditor@ons.org.

References

- Blaney, M., Shen, V., Kerner, J.A., Jacobs, B.R., Gray, S., Armfield, J., et al. (2006). Alteplase for the treatment of central venous catheter occlusion in children: Results of a prospective, open-label, single-arm study (The Cathflo® Activase® Pediatric Study). *Journal of Vascular and Interventional Radiology*, 17(11, Pt.1), 1745-1751.
- Cancer Care Ontario. (2007). Cancer as a chronic disease: Implications for health care in Ontario. Retrieved July 2007, from <http://www.cancercare.on.ca/AGM2007Presentation/AGMPresentation-MASTER-April25ts.ppt>
- Deitcher, S.R., Fesen, M.R., Kiproff, P.M., Hill, P.A., Li, X., McCluskey, E.R., et al. (2002). Safety and efficacy of alteplase for restoring function in occluded central venous catheters: Results of the Cardiovascular Thrombolytic to Open Occluded Lines Trial. *Journal of Clinical Oncology*, 20(1), 317-324.
- Dudrick, S.J. (2006). History of vascular access. *Journal of Parenteral and Enteral Nutrition*, 30(1, Suppl.), S47-S56.
- Fedan, J.S. (2003). Anticoagulant, antiplatelet, and fibrinolytic (thrombolytic) drugs. In C.R. Craig & R.E. Stitzel (Eds.), *Modern pharmacology with clinical applications* (6th ed., pp. 269-278). Lippincott Williams and Wilkins.
- Forauer, A.R., & Theoharis, C. (2003). Histologic changes in the human vein wall adjacent to indwelling central venous catheters. *Journal of Vascular and Interventional Radiology*, 14(9, Pt. 1), 1163-1168.
- Galloway, S., & Bodenham, A. (2004). Long-term central venous access. *British Journal of Anaesthesia*, 92(5), 722-734.
- Genentech, Inc. (2003). Cathflo® Activase® [Product insert]. South San Francisco, CA: Author.
- Grunfeld, E. (2006). Looking beyond survival: How are we looking at survivorship? *Journal of Clinical Oncology*, 24(32), 5166-5169.
- Hadaway, L.C. (2005). Reopen the pipeline for I.V. therapy. *Nursing*, 35(8), 54-61.
- Haire, W.D., Atkinson, J.B., Stephens, L.C., & Kotulak, G.D. (1994). Urokinase versus recombinant tissue plasminogen activator in thrombosed central venous catheters: A double-blinded, randomized trial. *Thrombosis and Haemostasis*, 72(4), 543-547.
- Haire, W.D., Deitcher, S.R., Mullane, K.M., Jaff, M.R., Firszt, C.M., Schulz, G.A., et al. (2004). Recombinant urokinase for restoration of patency in occluded central venous access devices: A double-blind, placebo-controlled trial. *Thrombosis and Haemostasis*, 92(3), 575-582.
- Hamilton, H. (2006a). Complications associated with venous access devices: Part one. *Nursing Standard*, 20(26), 43-50.
- Hamilton, H. (2006b). Complications associated with venous access devices: Part two. *Nursing Standard*, 20(27), 59-65.
- Horne, M.K., III. (2004). Thrombolytics for occluded catheters. *Critical Care Medicine*, 32(10), 2146-2147.
- Hurtubise, M.R., Bottino, J.C., Lawson, M., & McCredie, K.B. (1980). Restoring patency of occluded central venous catheters. *Archives of Surgery*, 115(2), 212-213.
- Infusion Nurses Society. (2006). *Policies and procedures for infusion nursing* (3rd ed.). Norwood, MA: Infusion Nurses Society.
- Jacobs, B.R. (2003). Central venous catheter occlusion and thrombosis. *Critical Care Clinics*, 19(3), 489-514.
- Jacobs, B.R., Haygood, M., & Hingl, J. (2001). Recombinant tissue plasminogen activator in the treatment of central venous catheter occlusion in children. *Journal of Pediatrics*, 139(4), 593-596.
- Journeycake, J.M., & Buchanan, G.R. (2006). Catheter-related deep venous thrombosis and other catheter complications in children with cancer. *Journal of Clinical Oncology*, 24(28), 4575-4580.
- Kerner, J.A., Jr., Garcia-Careaga, M.G., Fisher, A.A., & Poole, R.L. (2006). Treatment of catheter occlusion in pediatric patients. *Journal of Parenteral and Enteral Nutrition*, 30(1, Suppl.), S73-S81.

Kokotis, K. (2005). Cost containment and infusion services. *Journal of Infusion Nursing*, 28(3, Suppl.), S22-S32.

Liu, C.Y., Jain, V., Shields, A.F., & Heilbrun, L.K. (2004). Efficacy and safety of reteplase for central venous catheter occlusion in patients with cancer. *Journal of Vascular and Interventional Radiology*, 15(1, Pt. 1), 39-44.

Maki, D.G., Stolz, S.M., Wheeler, S., & Mermel, L.A. (1997). Prevention of central venous catheter-related bloodstream infection by use of an antiseptic-impregnated catheter. A randomized, controlled trial. *Annals of Internal Medicine*, 127(4), 257-266.

Middleton, G., & Ruzevick, B. (2004). Alteplase (Cathflo® Activase®). *Clinical Journal of Oncology Nursing*, 8(4), 417-418.

Moll, S., Kenyon, P., Bertoli, L., De Maio, J., Homesley, H., & Deitcher, S.R. (2006). Phase II trial of alteplase, a novel-acting fibrin degradation agent, for occluded central venous access devices. *Journal of Clinical Oncology*, 24(19), 3056-3060.

Moureau, N., Poole, S., Murdock, M.A., Gray, S.M., & Semba, C.P. (2002). Central venous catheters in home infusion care: Outcomes analysis in 50,470 patients. *Journal of Vascular and Interventional Radiology*, 13(10), 1009-1016.

Ng, R., Li, X., Tu, T., & Semba, C.P. (2004). Alteplase for treatment of occluded peripherally inserted central catheters: Safety and efficacy in 240 patients. *Journal of Vascular and Interventional Radiology*, 15(1, Pt. 1), 45-49.

Oncology Nursing Society. (2004). *Access device guidelines* (2nd ed.). Pittsburgh, PA: Author.

Ottawa Hospital. (2006, July). *Central venous access device (CVAD): Restoring patency for thrombotic occlusion. Nursing policy, procedure, protocol manual*. Ottawa, Canada: Author.

Prandoni, P., Piccioli, A., & Griolami, A. (1999). Cancer and venous thromboembolism: An overview. *Haematologica*, 84(5), 437-445.

Ponec, D., Irwin, D., Haire, W.D., Hill, P.A., Li, X., & McCluskey, E.R. (2001). Recombinant tissue plasminogen activator (alteplase) for restoration of flow in occluded central venous access devices: A double-blind placebo-controlled trial—The Cardiovascular Thrombolytic to Open Occluded Lines (COOL) efficacy trial. *Journal of Vascular and Interventional Radiology*, 12(8), 951-955.

Registered Nurses Association of Ontario. (2002). *Toolkit: Implementation of clinical practice guidelines*. Retrieved December 1, 2006, from http://www.rnao.org/Storage/12/668_BPG_Toolkit.pdf

Registered Nurses Association of Ontario. (2004). *Assessment and device selection for vascular access*. Retrieved May 1, 2007, from http://www.rnao.org/Storage/11/531_BPG_assess_device_select_vascular.pdf

Registered Nurses Association of Ontario. (2005). *Care and maintenance to reduce vascular access complications*. Toronto, Canada: Author.

Shen, V., Li, X., Murdock, M., Resnansky, L., McCluskey, E.R., & Semba, C.P. (2003). Recombinant tissue plasminogen activator (alteplase) for restoration of function to occluded central venous catheters in pediatric patients. *Journal of Pediatric Hematology/Oncology*, 25(1), 38-45.

Steiger, E. (2006). Dysfunction and thrombotic complications of vascular access devices. *Journal of Parenteral and Enteral Nutrition*, 30(1, Suppl.), S70-S72.

Valji, K. (2000). Evolving strategies for thrombolytic therapy of peripheral vascular occlusion. *Journal of Vascular and Interventional Radiology*, 11(4), 411-420.

Wingerter, L. (2003). Vascular access device thrombosis. *Clinical Journal of Oncology Nursing*, 7(3), 345-348.

Receive free continuing nursing education credit for reading this article and taking a brief quiz online. To access the test for this and other articles, visit <http://evaluationcenter.ons.org>. After entering your Oncology Nursing Society profile username and password, select CNE Listing from the left-hand tabs. Scroll down to *Clinical Journal of Oncology Nursing* and choose the test(s) you would like to take.

The Oncology Nursing Advisory Board

The Oncology Nursing Advisory Board developed the previous guidelines for management of central venous access device occlusions for patients receiving cancer treatment in centers. The following people were members of the board.

Joanne L. Allen, RN, Allan Blair Cancer Centre, Saskatchewan Cancer Agency, Regina, Canada
 Kathy Beattie, RN, CON(C), Sunnybrook Odette Cancer Centre, Toronto, Canada
 Sylvie Belanger, inf., MSc.inf., CSIO(C), Hôpital du Sacre-Cœur de Montréal, Montreal, Canada
 Linda Robb Blenderman, RN, MSc, CON(C), Oncology Cancer Centre of Southeastern Ontario, Kingston, Canada
 Megan Black, RN, CON(C), Saskatoon Cancer Centre, Saskatoon, Canada
 Helen Brown, RN, BN, Saint John Regional Hospital, Saint John, Canada
 Miriam Corne, BN, MEd, CON(C), CancerCare Manitoba, Winnipeg, Canada

Cindy Cummings Winfield, RN, BScN, CON(C), Cross Cancer Institute, Edmonton, Canada
 Kathy Fitzgerald, RN, BN, CON(C), Cancer Care Program, Eastern Health, Saint John, Canada
 Inara H. Karrei, RN, BScN, MEd, CON(C), Ottawa Regional Cancer Centre, Ottawa, Canada
 Marcia Langhorn, RN, CON(C), London Regional Cancer Program, London, Canada
 Lucie Laporte, inf. clinicienne, csio, Hôpital Charles Le Moyne, Réseau Cancer Montérégie, Greenfield Park, Quebec, Canada
 Andrea Miller, RN, BScN, MEd, CON(C), Hematology Oncology, Hamilton Health Sciences, Hamilton, Canada
 Tayreez Mushani-Kanji, RN, BScN, CON(C), CHPCN(C), Cross Cancer Institute, Edmonton, Canada
 Pamela Savage, RN, MA, Ed, CON(C), Princess Margaret Hospital, University Health Network, Toronto, Canada
 Suzanne Ste. Croix, RN, Grey Bruce Health Services, Owen Sound, Canada