



# An Unusual Cause of Shoulder Pain

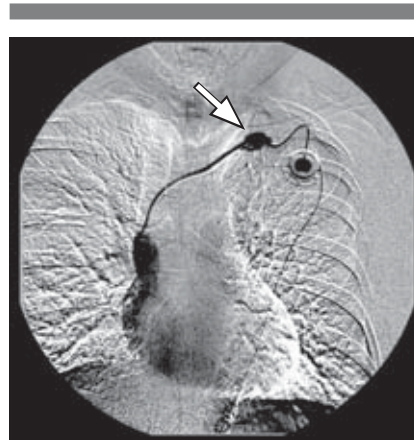
Lisa Schulmeister, RN, MN, CS, OCN®

## Case Study

A central venous port was implanted in the left infraclavicular area of Ms. W, a 70-year-old woman with recurrent colon cancer. Two days later, she complained of pain in her left shoulder while receiving her first course of chemotherapy (irinotecan 125 mg/m<sup>2</sup>, 5-fluorouracil 500 mg/m<sup>2</sup>, and leucovorin 200 mg/m<sup>2</sup>, all given as IV boluses weekly for four weeks followed by a two-week rest period). Ms. W's nurse reassured her that shoulder pain was to be expected because the port had been inserted recently. The presence or absence of a blood return was not documented in the medical record; however, the port was described as "flushing easily, without resistance."

When Ms. W's port was flushed with normal saline prior to her second chemotherapy treatment, she told the same nurse that her left shoulder was starting to burn. The nurse pressed down on the noncoring needle and informed the patient that it was secure and flush with the bottom of the portal reservoir. The nurse then flushed the port with a second saline-filled syringe, documented that the port flushed easily and had a "slight pink-tinged blood return," and told Ms. W that she was "just feeling the cold fluid going in." When the nurse administered the chemotherapy, the woman complained of increasing discomfort but was reassured that it resulted from the cool temperature of the drugs being infused. On completion of the chemotherapy treatment, Ms. W reported that her shoulder "burned terribly." The nurse replied that the area around the port "still must be sensitive" and suggested that the patient place a heating pad on her shoulder when she returned to her home.

Ms. W called the surgeon who had implanted her port, described her discomfort, and asked whether shoulder pain should be expected during future chemotherapy treatments. The surgeon ordered a contrast dye study (venogram) (see Figure 1), which showed that dye was leaking from the catheter of the port into the subcutaneous tissue. The port was removed and visually inspected by the surgeon. Although no catheter



**FIGURE 1. CATHETER DYE STUDY (VENOGRAM) SHOWING LEAKAGE OF CONTRAST AGENT FROM THE CATHETER**

Note. Copyright 2005 by Lisa Schulmeister. Reprinted with permission.

damage was discovered on first inspection, when the catheter tip was pinched closed and saline was injected into the port, saline squirted from the catheter (see Figure 2). A small linear slit was apparent on closer examination of the catheter.

## Discussion

Patients with newly inserted central venous ports often experience localized pain secondary to the creation and closure of the incision and tissue tugging when a subcutaneous pocket is made for placement of the portal reservoir. However, postprocedure pain usually is experienced on the day of implantation, may persist for a few days, and is characterized as mild and superficial in nature. In contrast, moderate to severe pain that is felt deeper in the infraclavicular or shoulder area and occurs only when medications or fluids are administered needs to be investigated with a dye study. Possible causes of this type of pain are incomplete noncoring needle insertion, portal reservoir or catheter separation, and catheter damage.

If the tip of the noncoring needle is inserted incompletely and located above the port septum and below the skin surface, medications will be delivered into the subcutaneous tissue. Inadvertent subcutaneous administration of IV chemotherapy may cause discomfort or an extravasation injury if vesicants are administered (Schulmeister & Camp-Sorrell, 2000).

Shoulder pain on the side of an implanted port also may be caused by device separation or disconnection. Implanted ports consist of two main parts, the portal reservoir (or body) and catheter. Ports are manufactured as single-piece, preconnected devices or as two-piece devices that require attachment of the catheter to the portal reservoir during the implantation procedure. Separation of a two-piece port at the portal reservoir or catheter connection can occur if the two components are not fastened securely during implantation or separate at a later time. Slippage of the O-ring, which attaches the catheter to the reservoir in two-piece systems, was suspected to cause portal reservoir or catheter separation in a number of case reports (Carr, 1989; Hall, Cedermark, & Swedenborg, 1989; Kock, Pietsch, Krause, Wilke, & Eigler, 1998). In two other reported cases, the precise cause of the separations could not be ascertained (Saifi, MacDowell, Khouri, & Webster, 1987).

Implanted port catheters can rupture (develop a hole or tear) or fracture (shear completely and break apart) and embolize to various locations, such as the heart and lungs. Catheter compression between the clavicle and first rib over a prolonged period of time produces mechanical friction that weakens the catheter and is termed costoclavicular pinching or the "pinch-off syndrome." When a catheter appears to be compressed or indented as it passes beneath the clavicle (i.e., the pinch-off sign), the risk of catheter rupture and fracture increases.

*Lisa Schulmeister, RN, MN, CS, OCN®, is a self-employed oncology nursing consultant in River Ridge, LA.*

Digital Object Identifier: 10.1188/05.CJON.476-477